

# “Lifting” the Standards in Breast Reconstruction: Pushing the Aesthetic Envelope

Meredith Collins, MD, FACS

Section Chief, Division of Plastic Surgery


Ochsner Health

The logo for Ochsner Health, featuring a stylized blue and yellow icon to the left of the text "Ochsner Health" in a bold, blue, sans-serif font.

 Ochsner Health

# Disclosures

- Received an honorarium from RTI/Evergen



# Goals of Skin Reduction in Breast Reconstruction

Cosmetic-  
appearing result

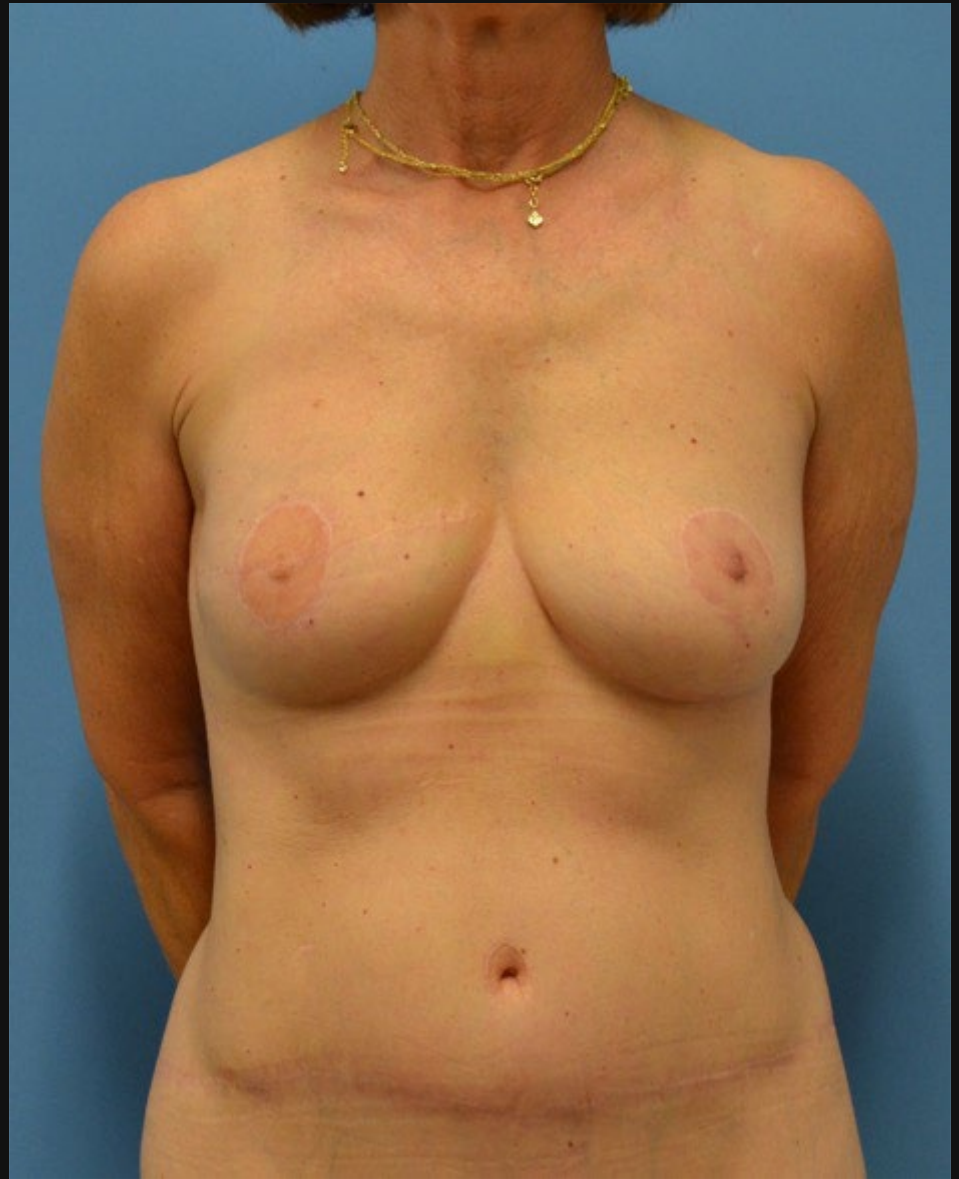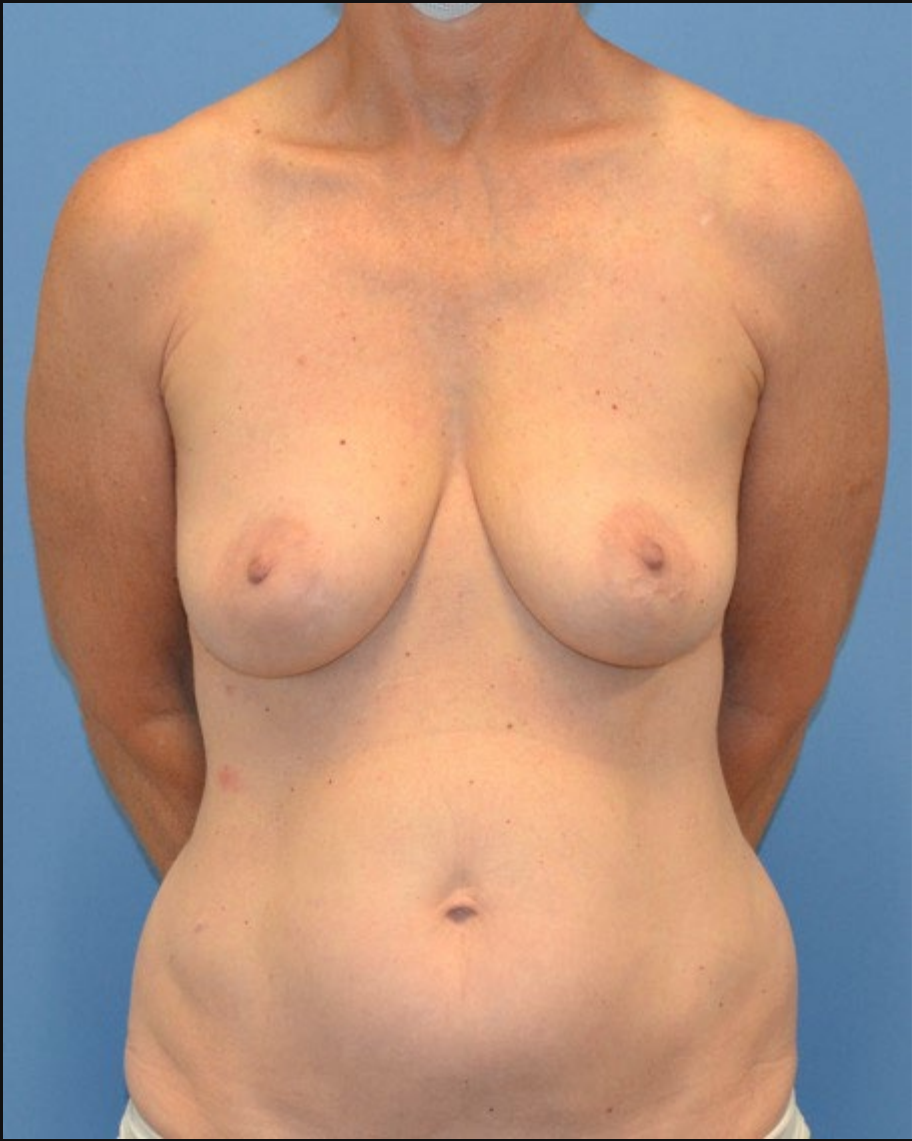Improved/lifted  
breast shape

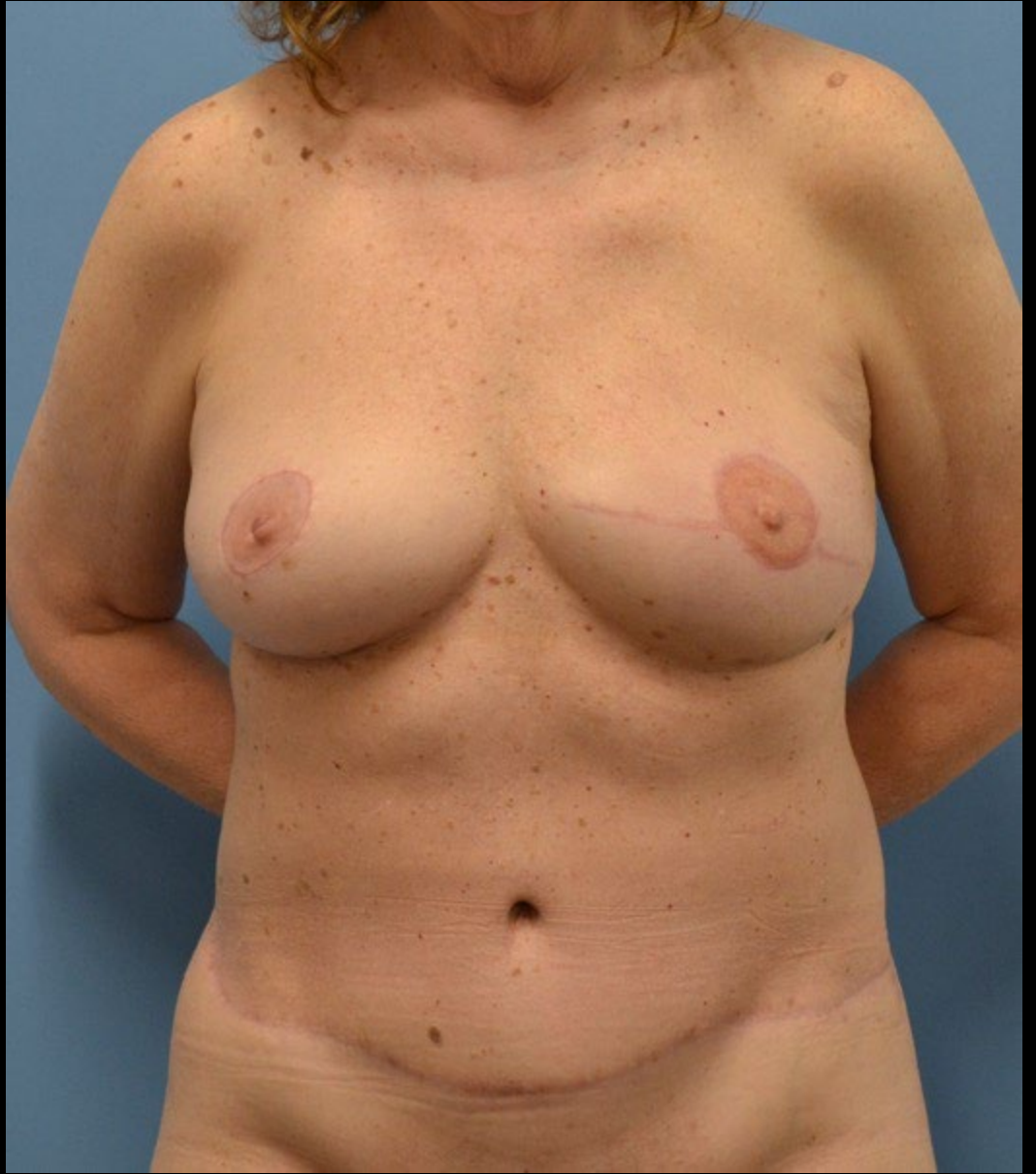
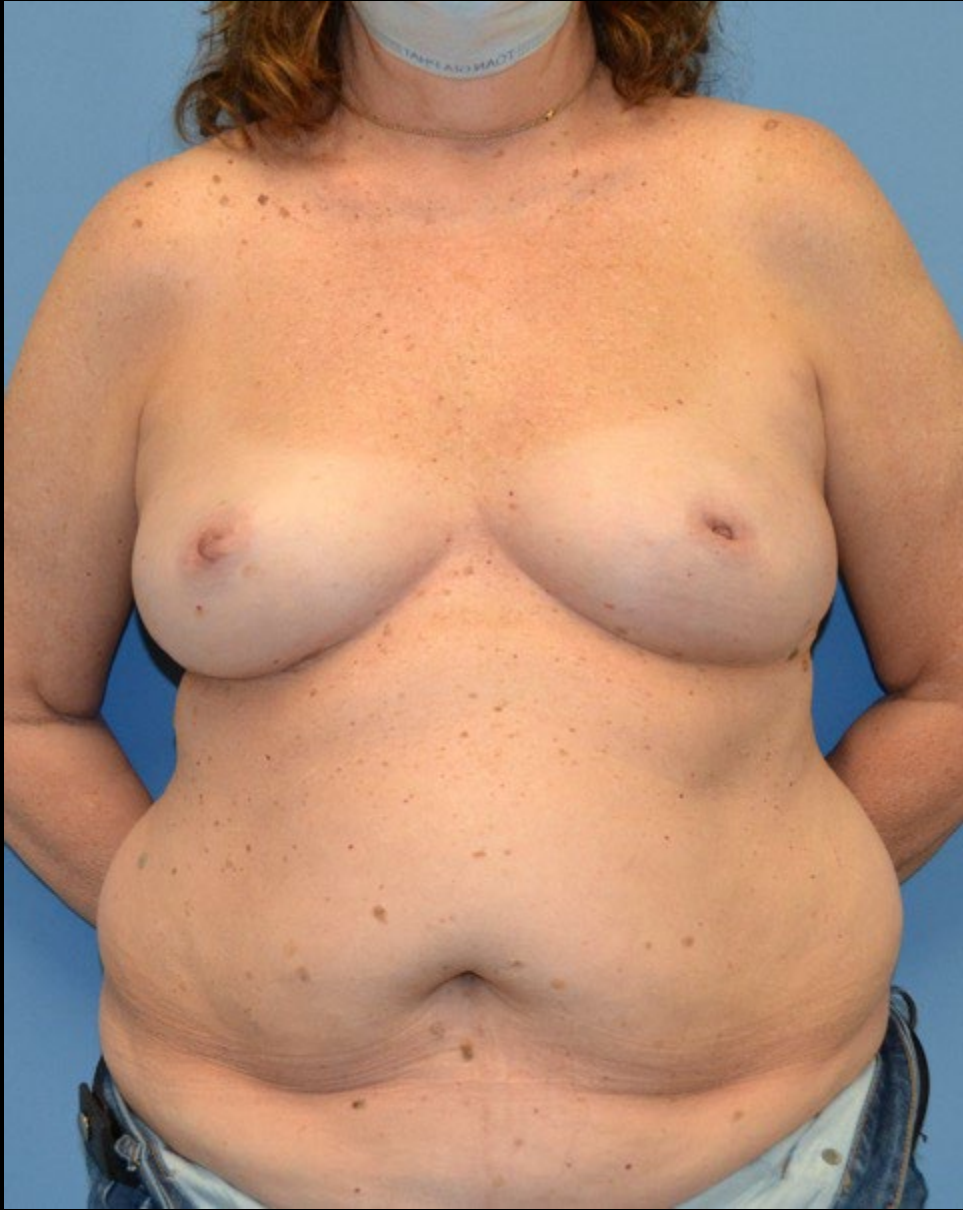Avoidance of  
transverse  
mastectomy  
incision

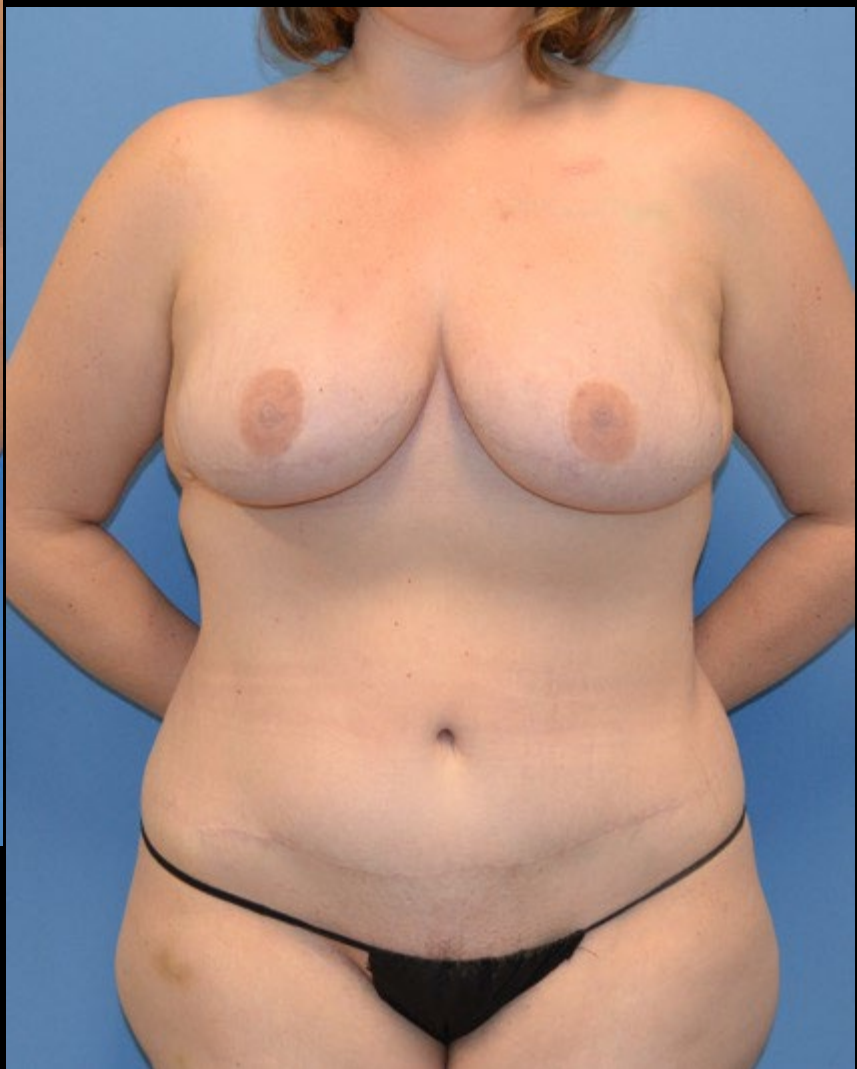
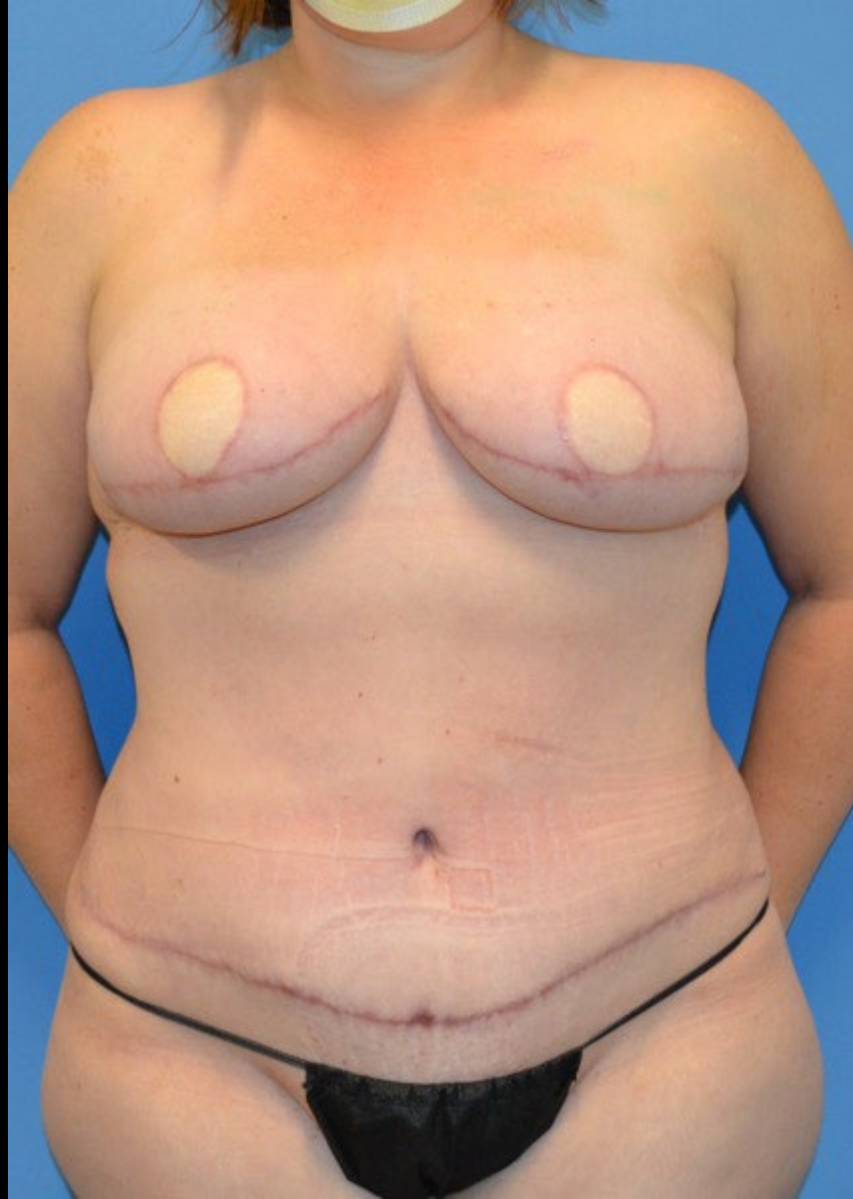
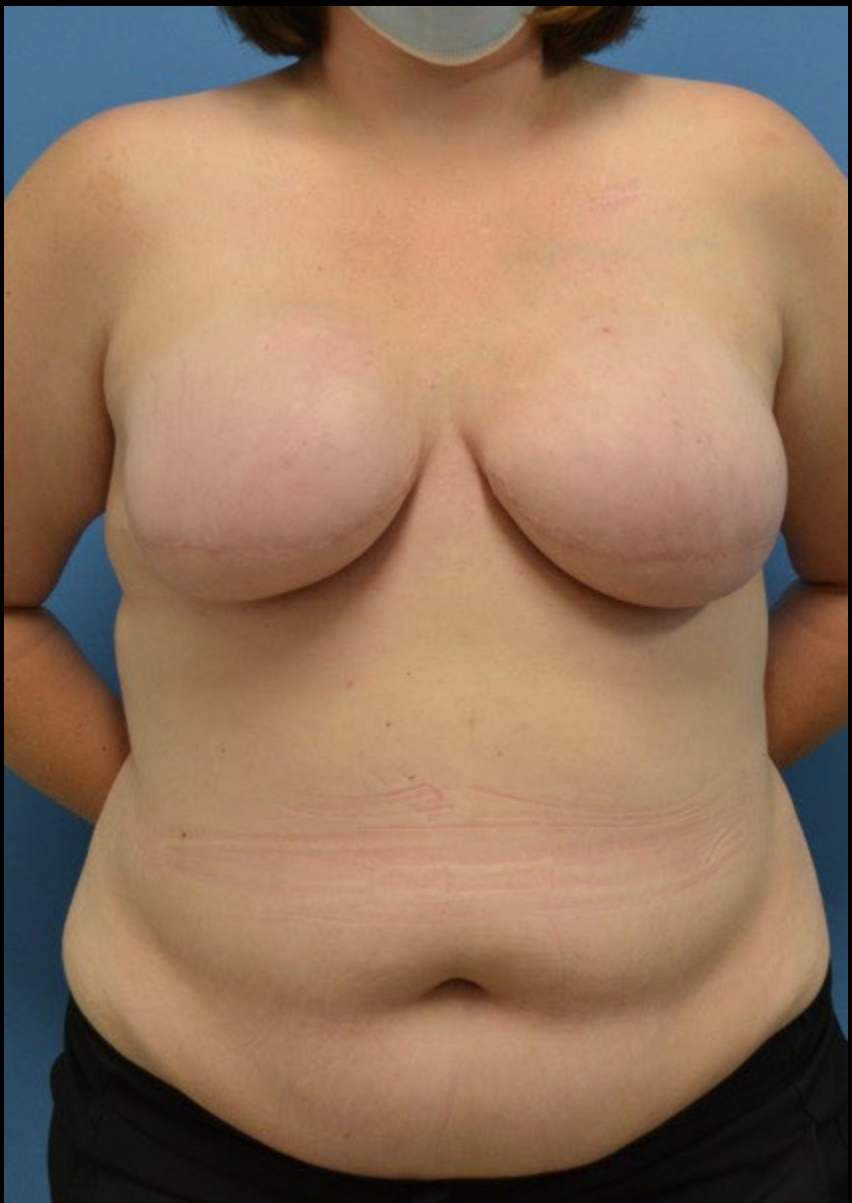Preservation of  
nipple areola  
complex

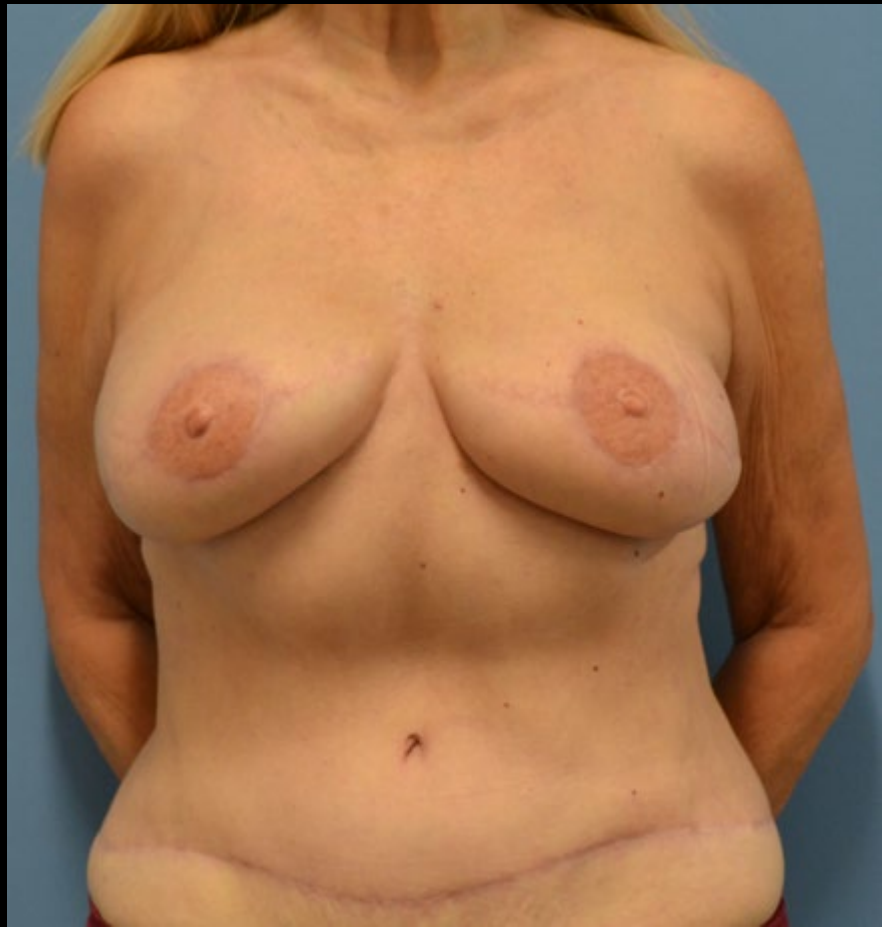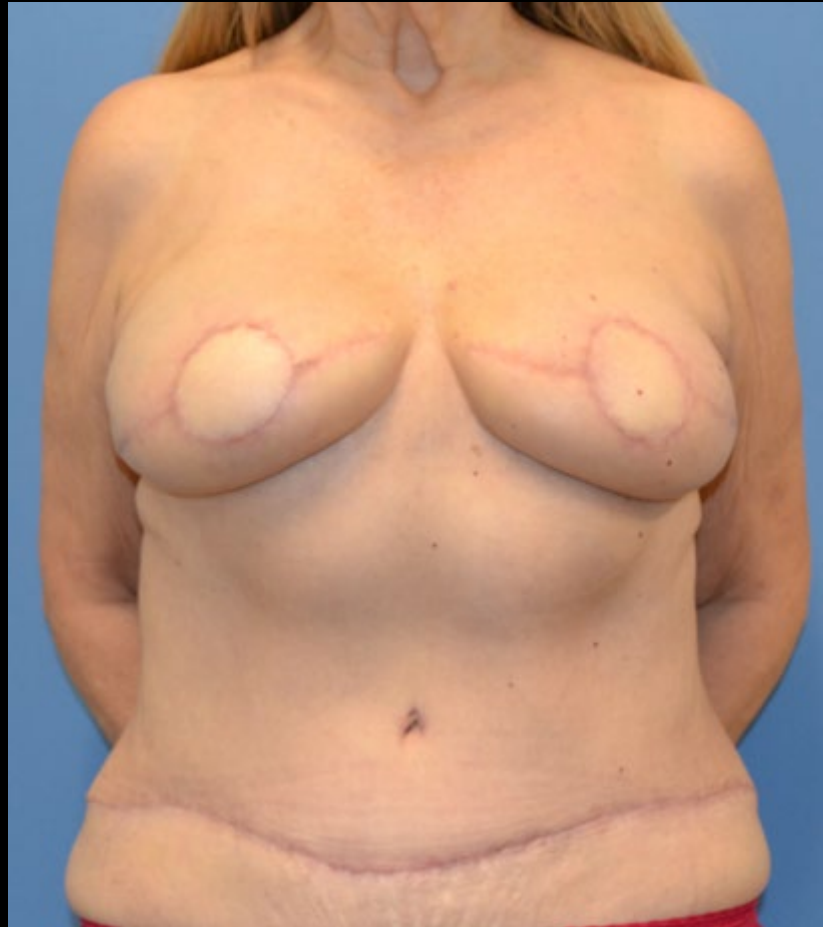
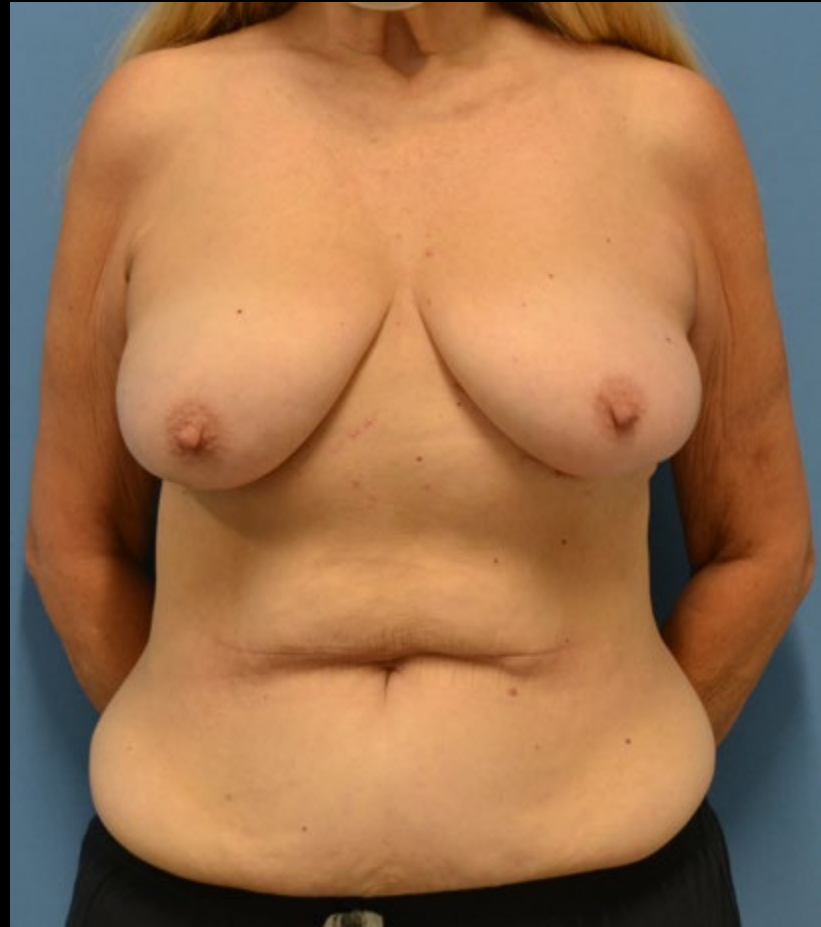Camouflage the  
Mastectomy

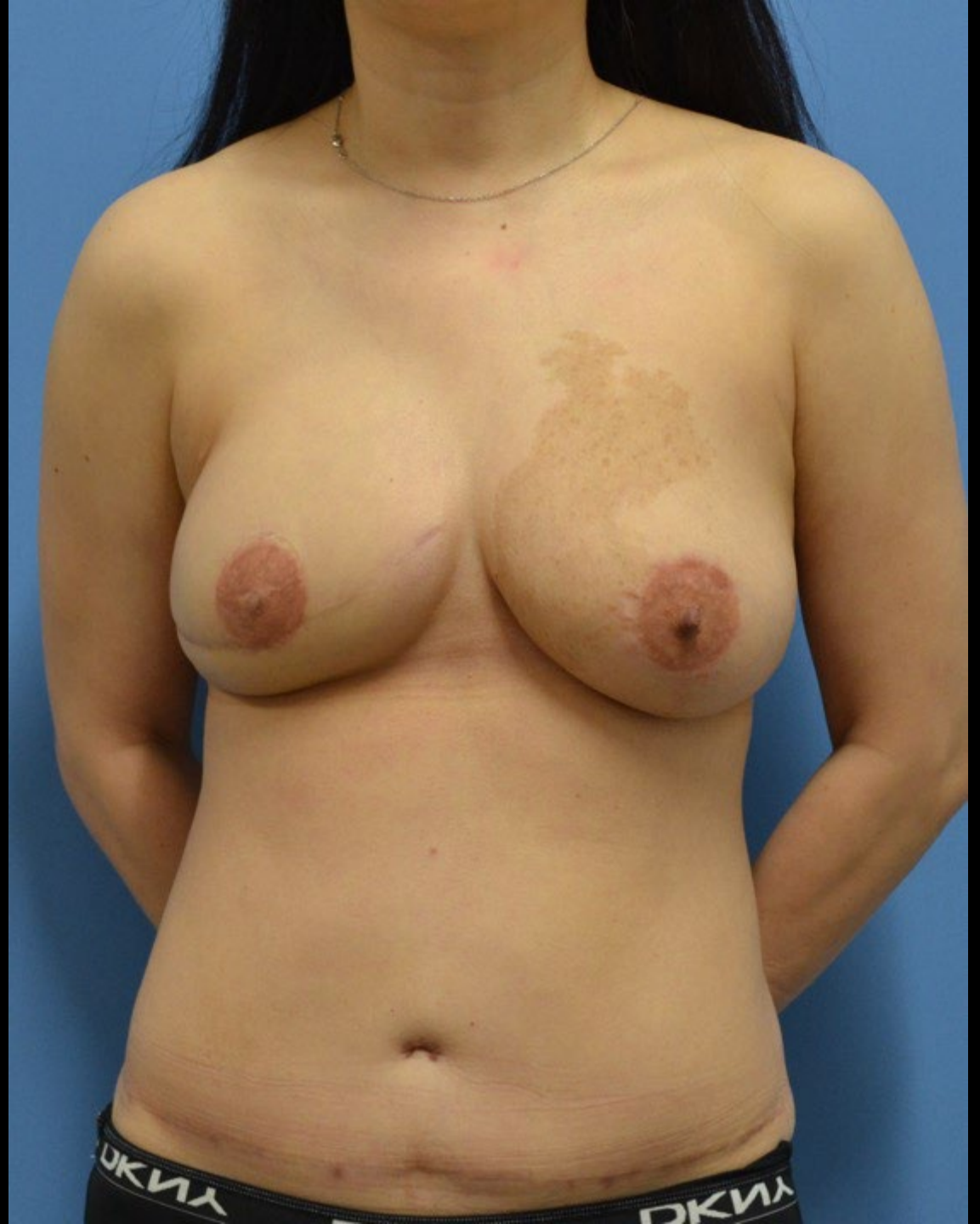
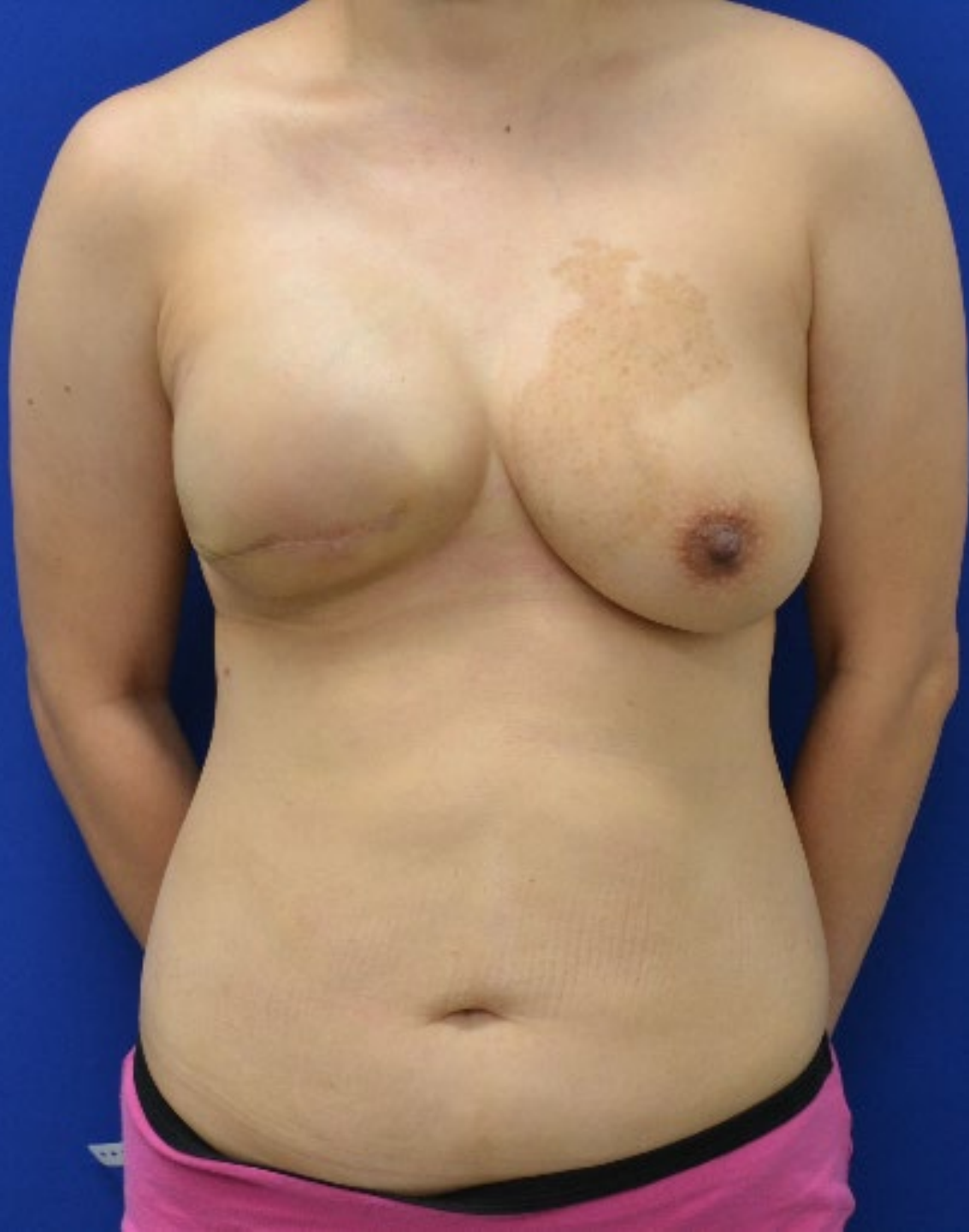


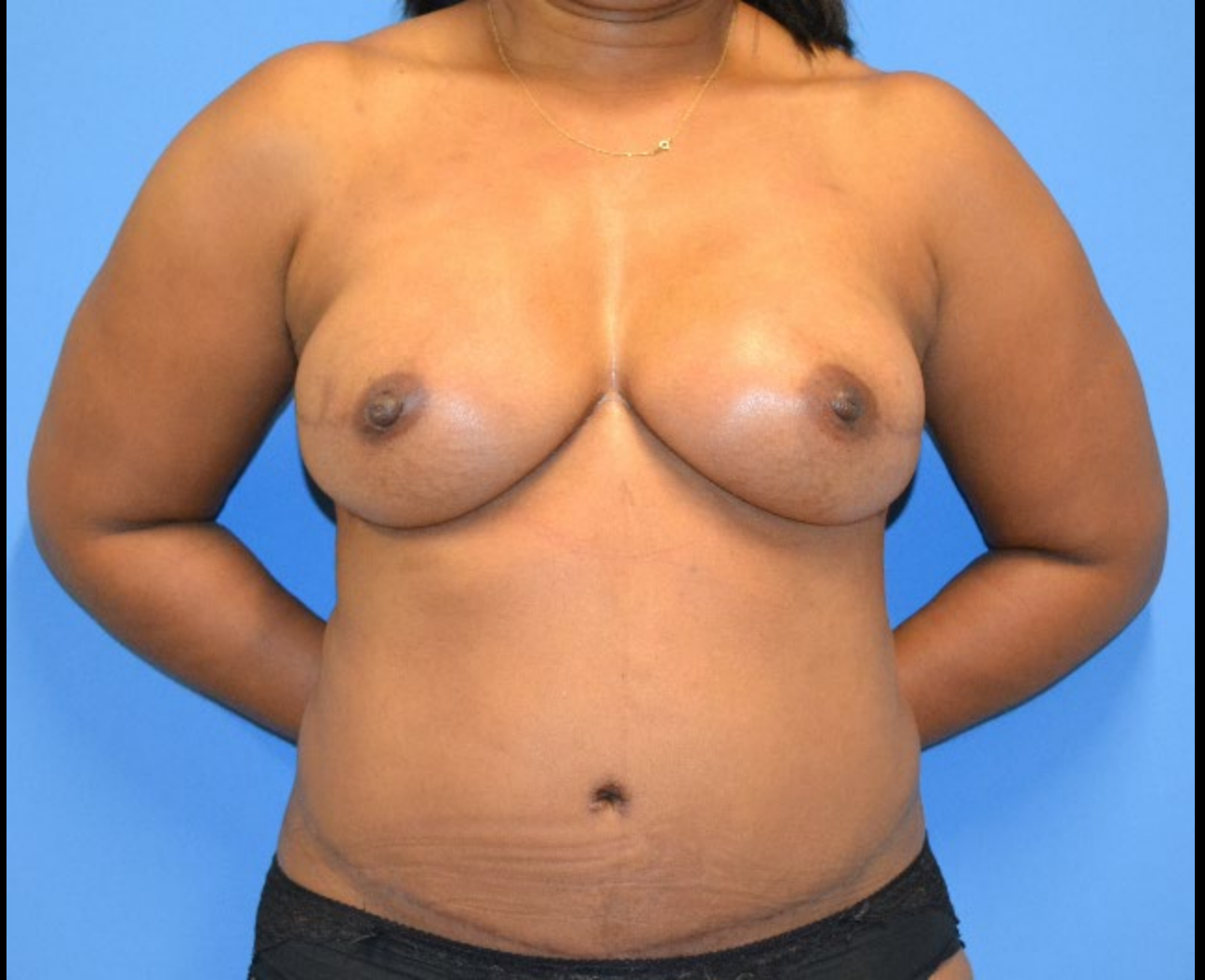
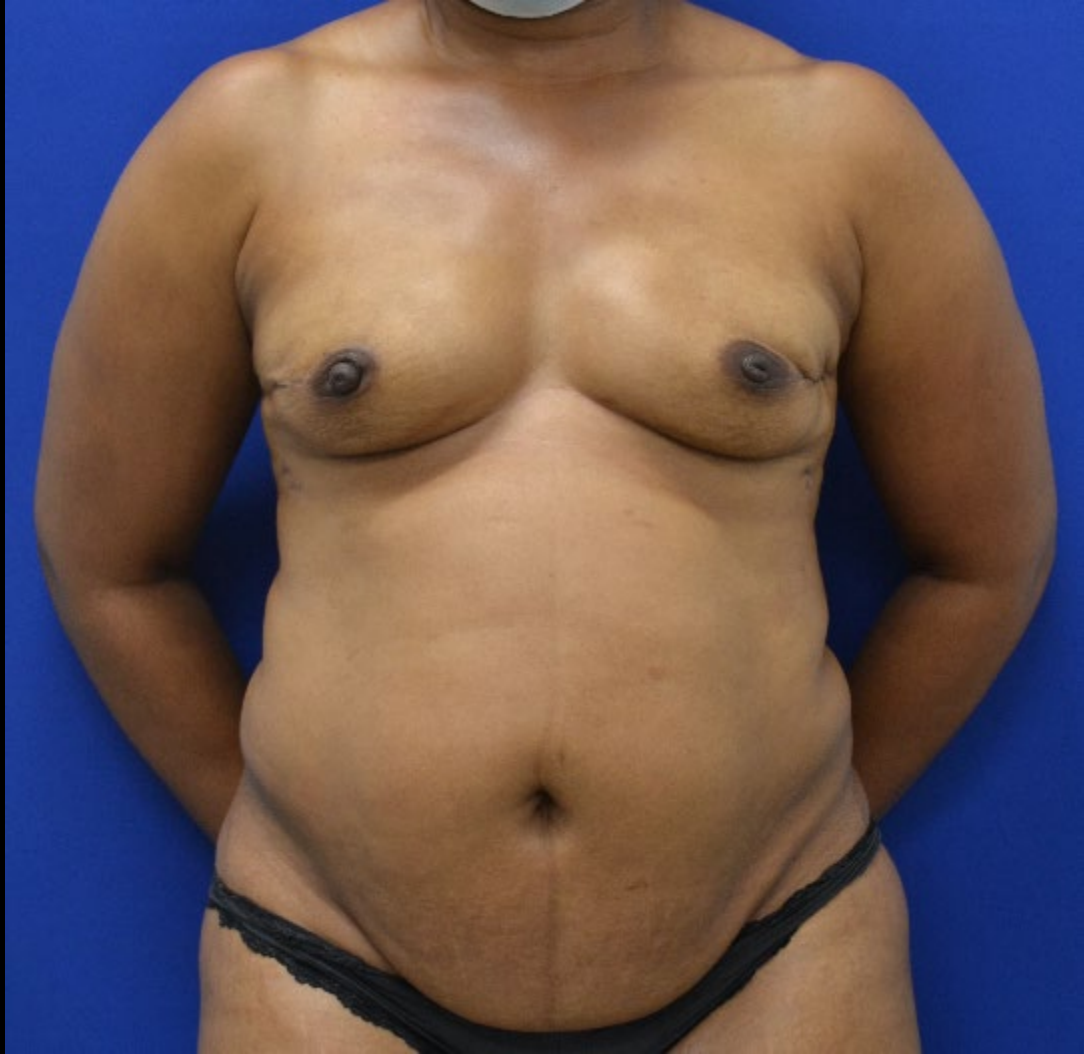


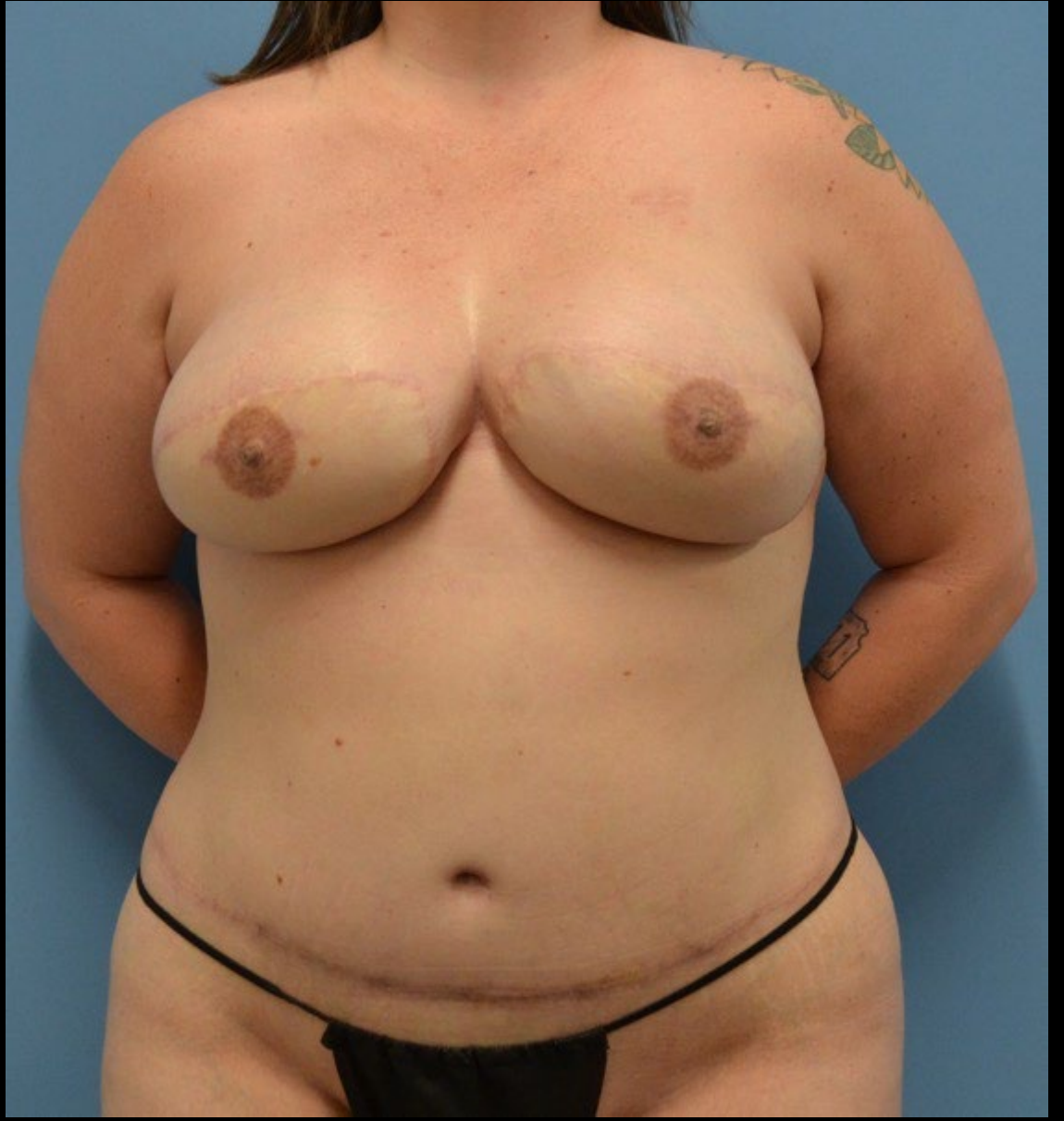
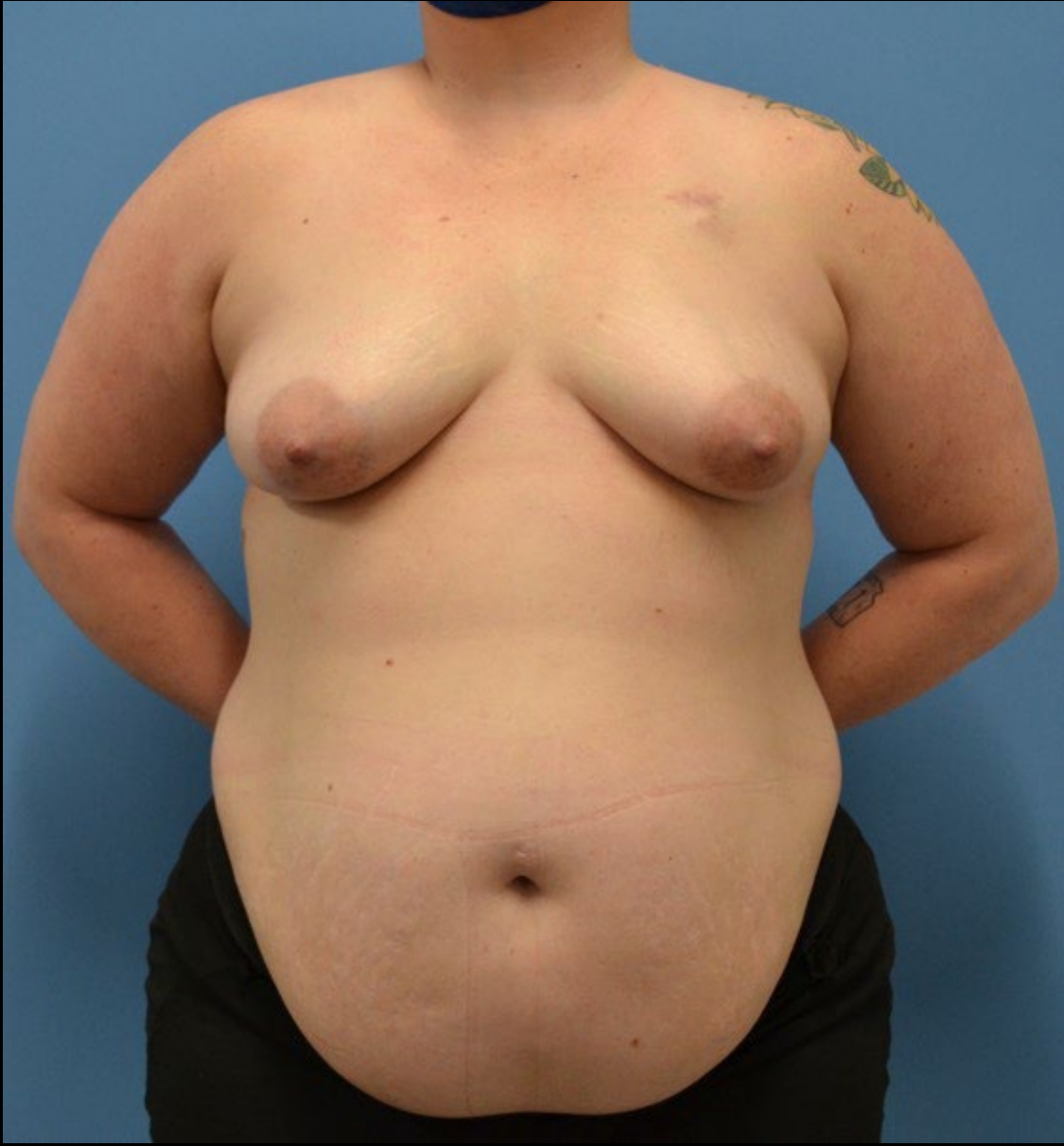


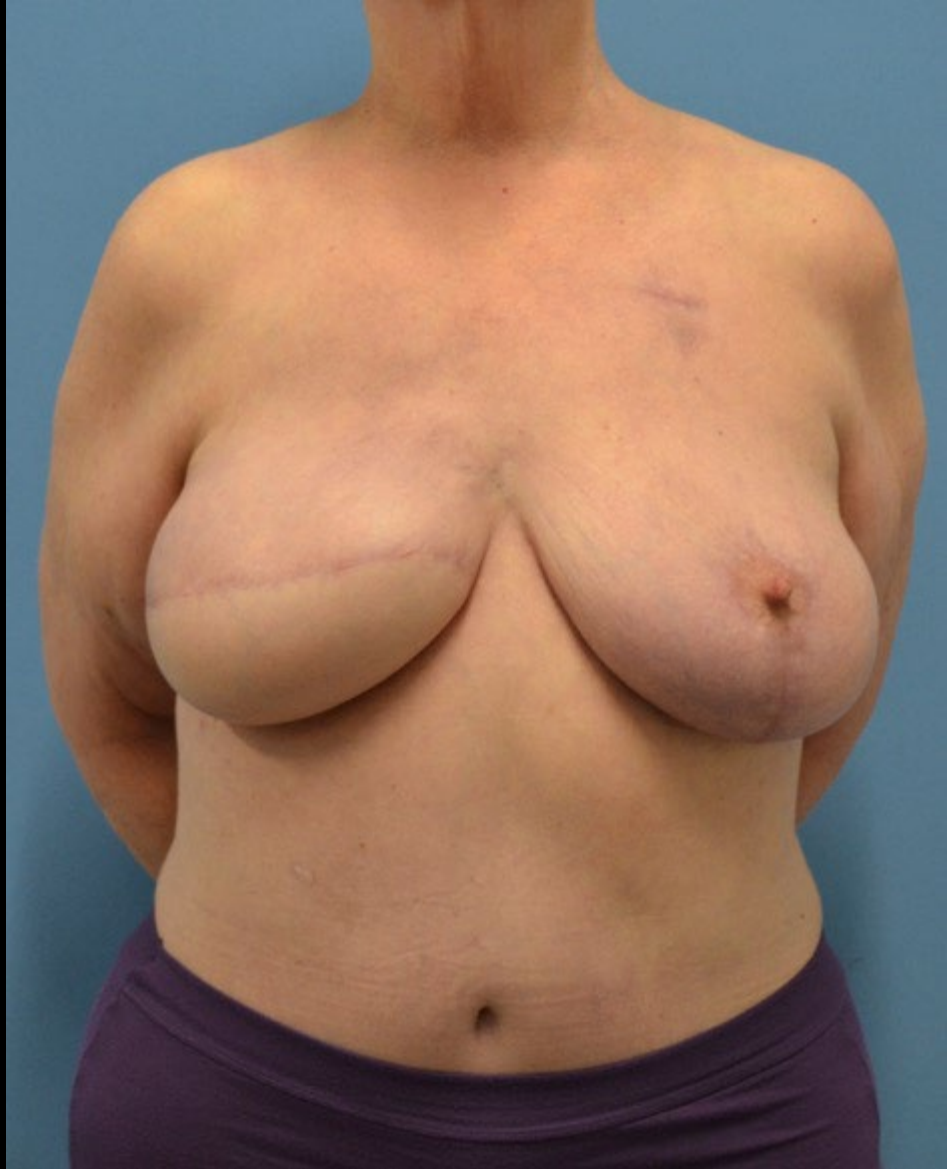
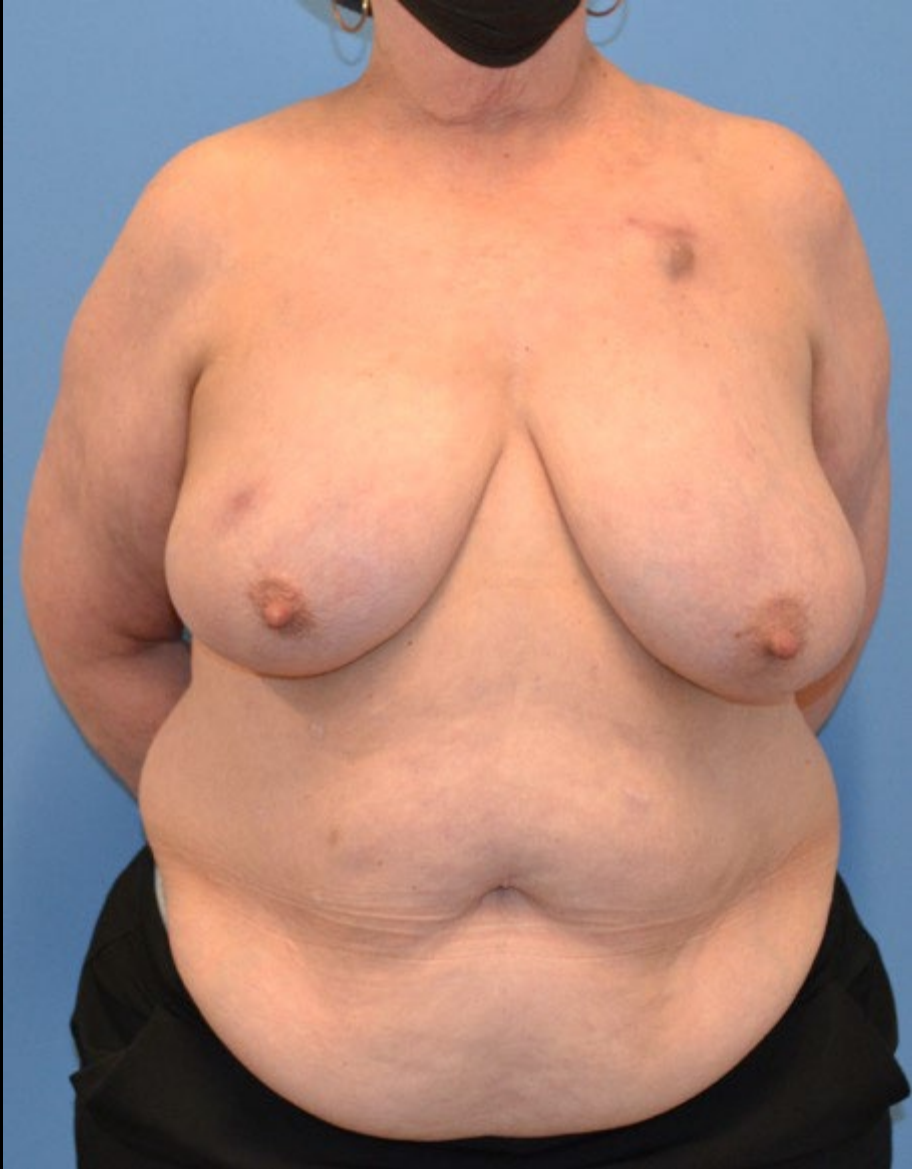
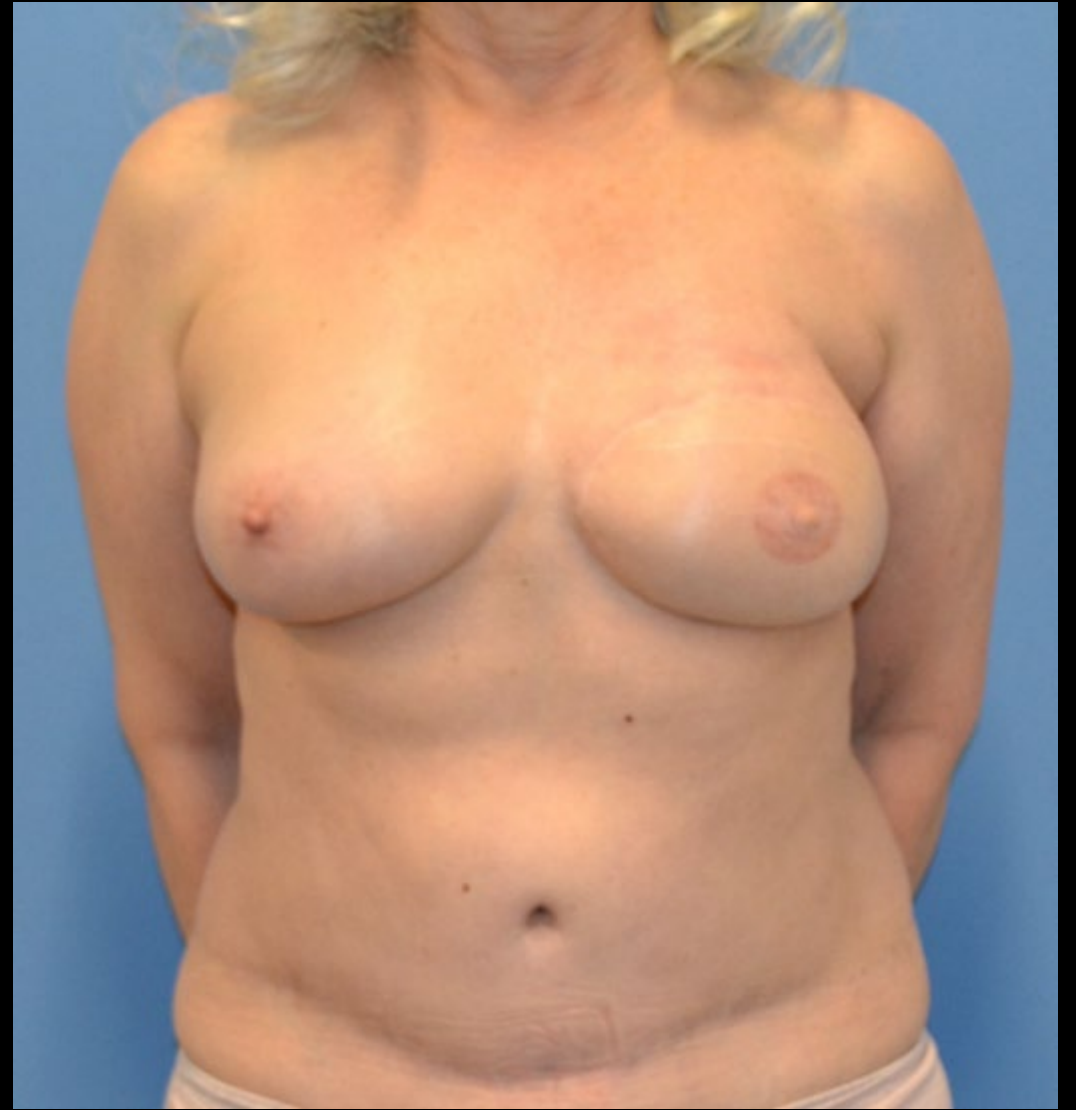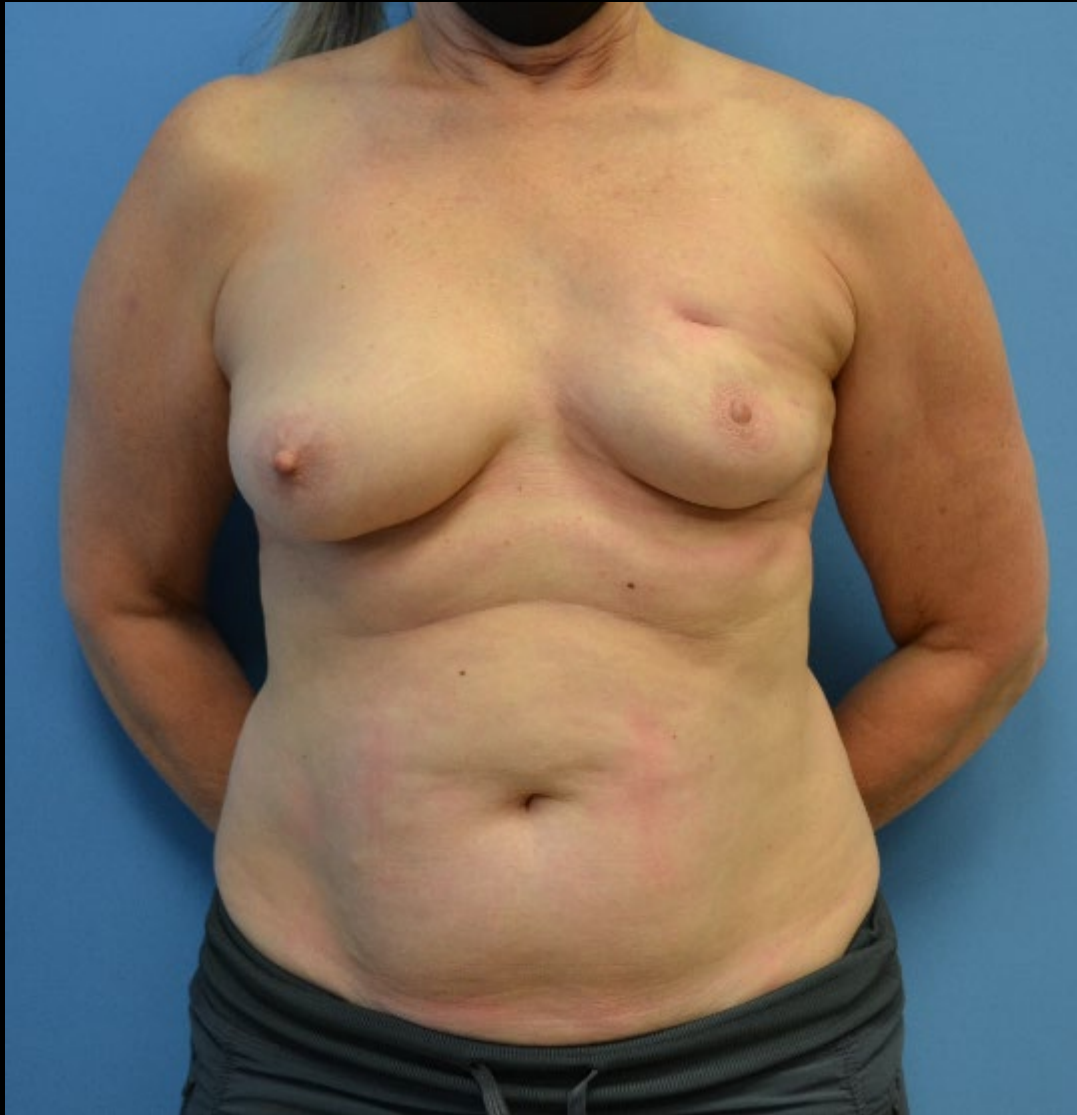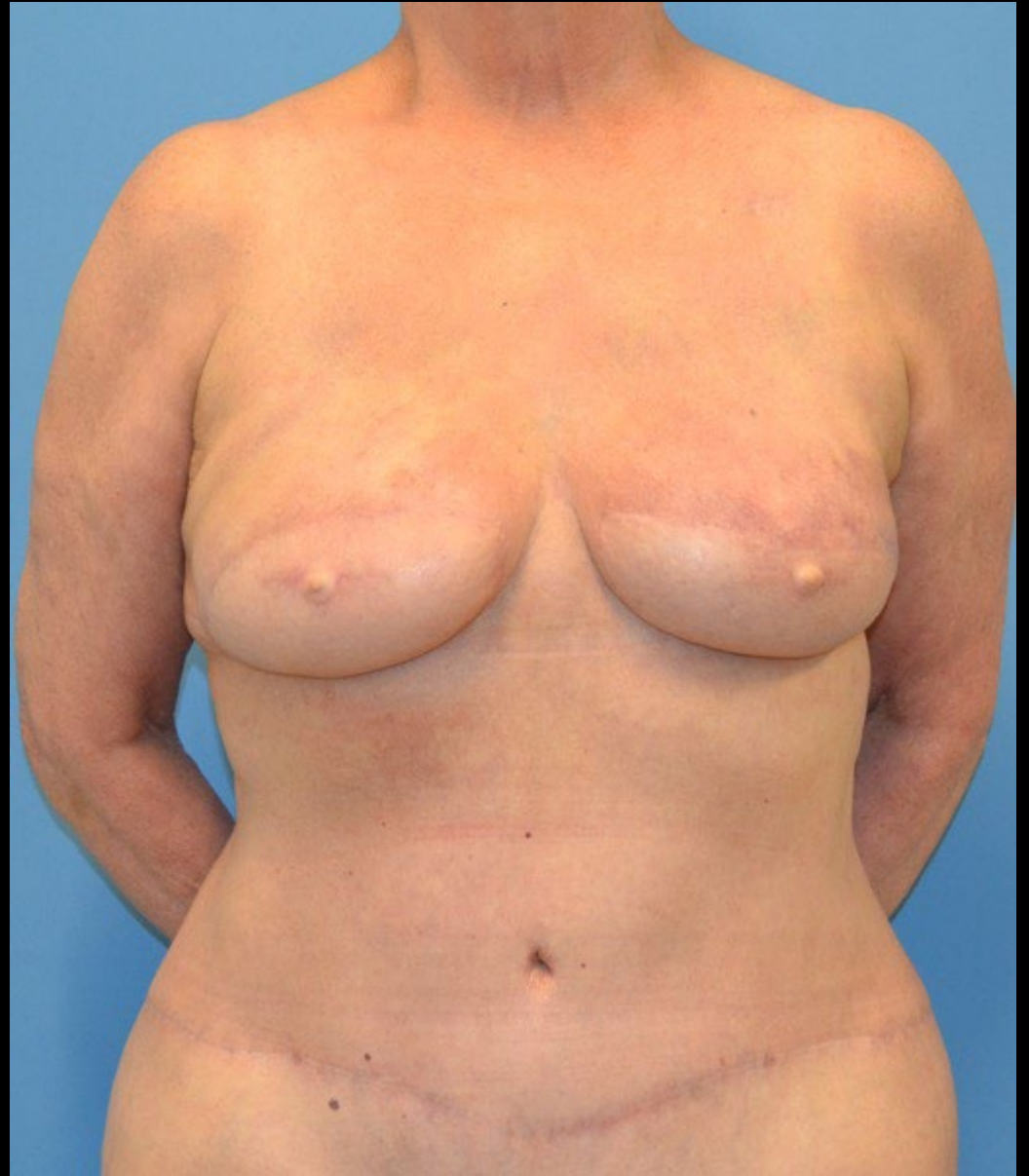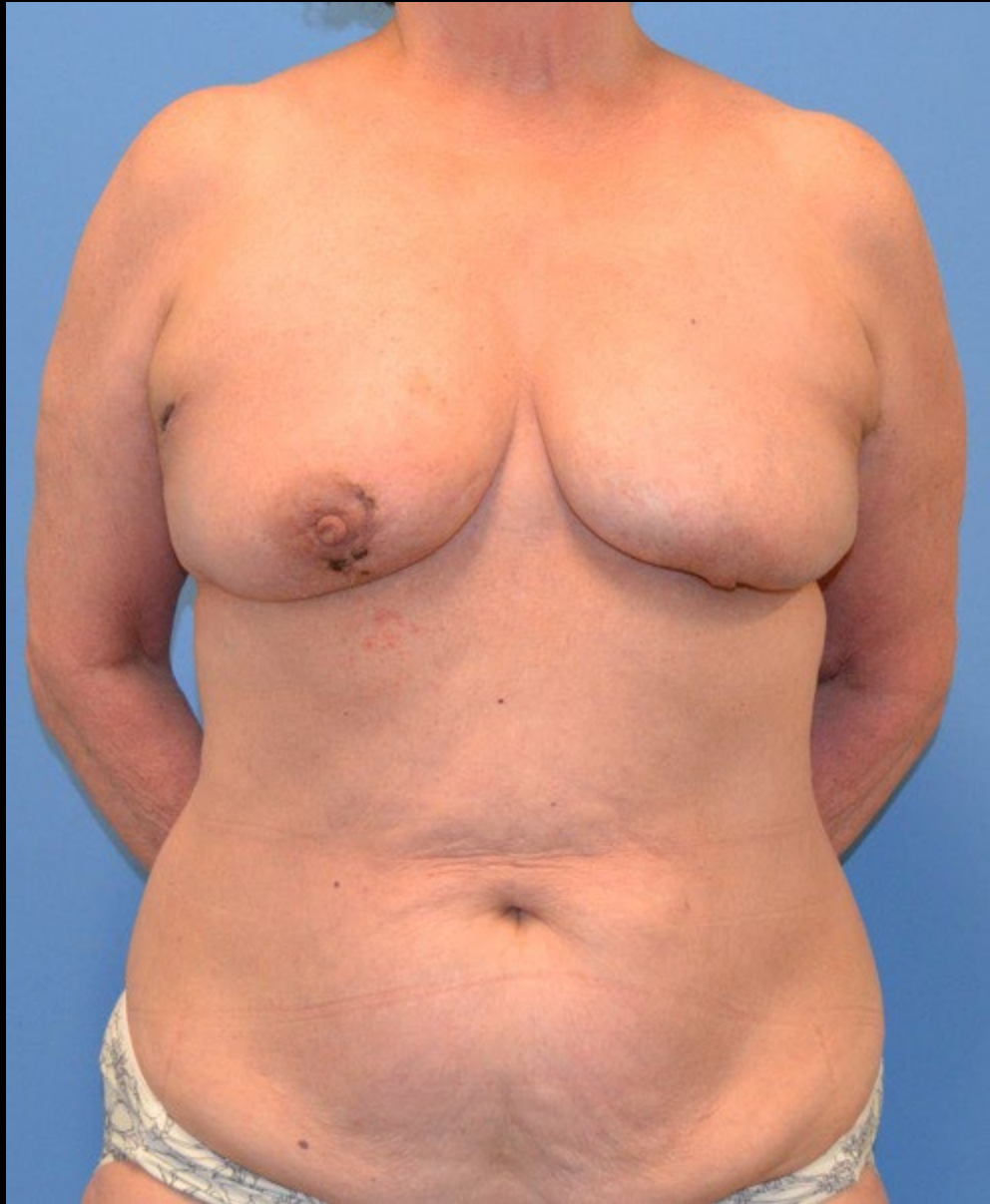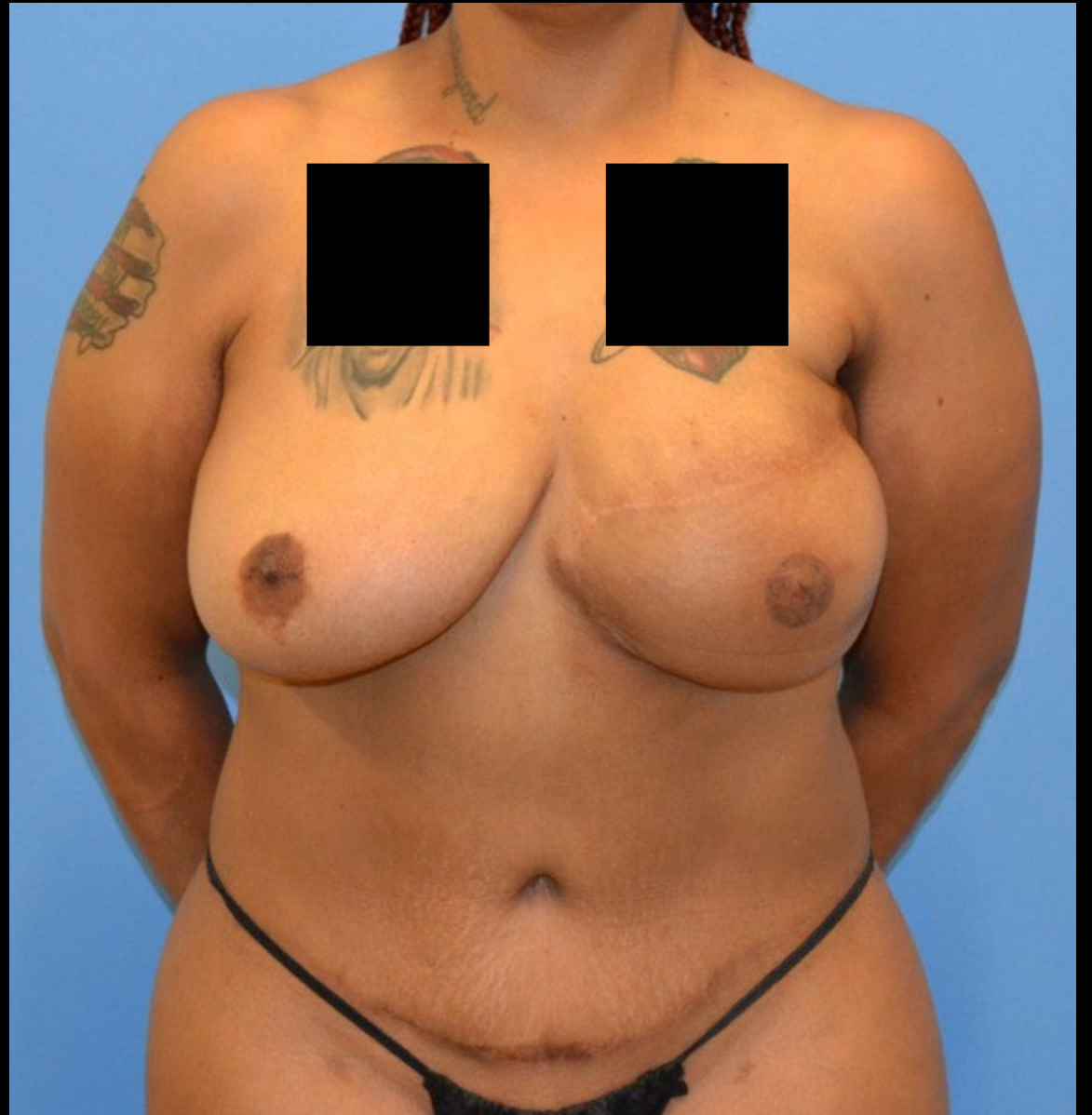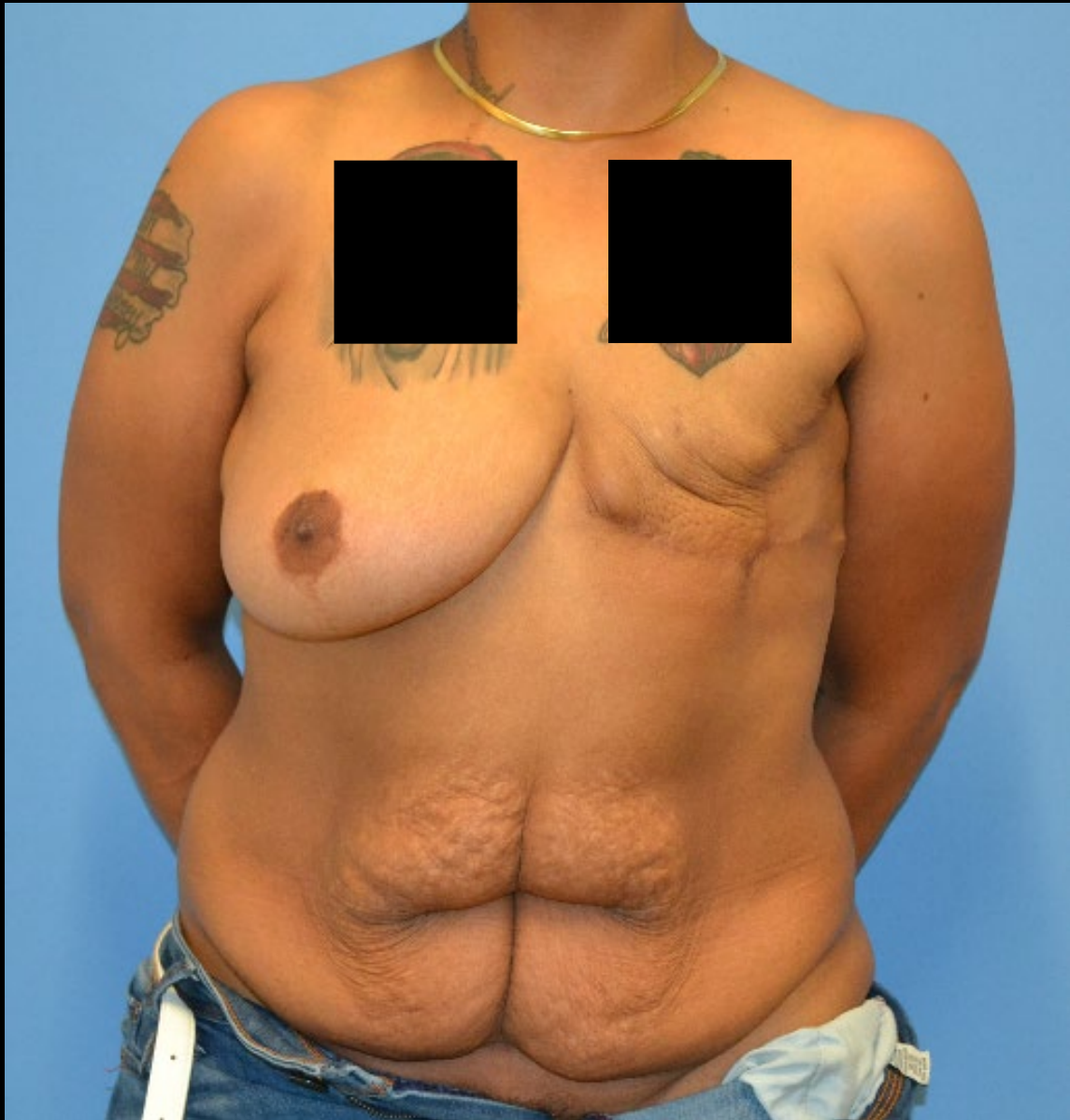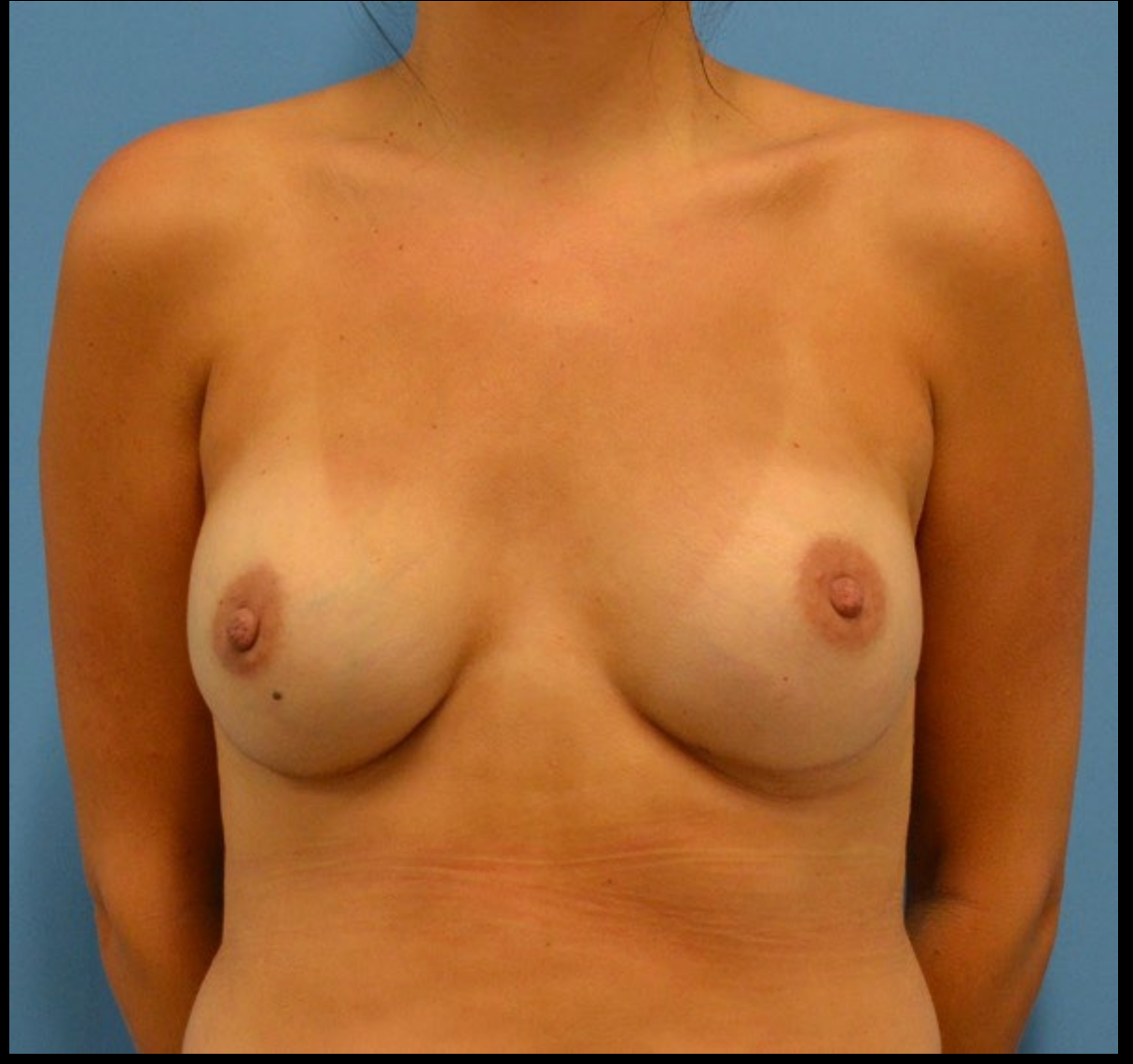








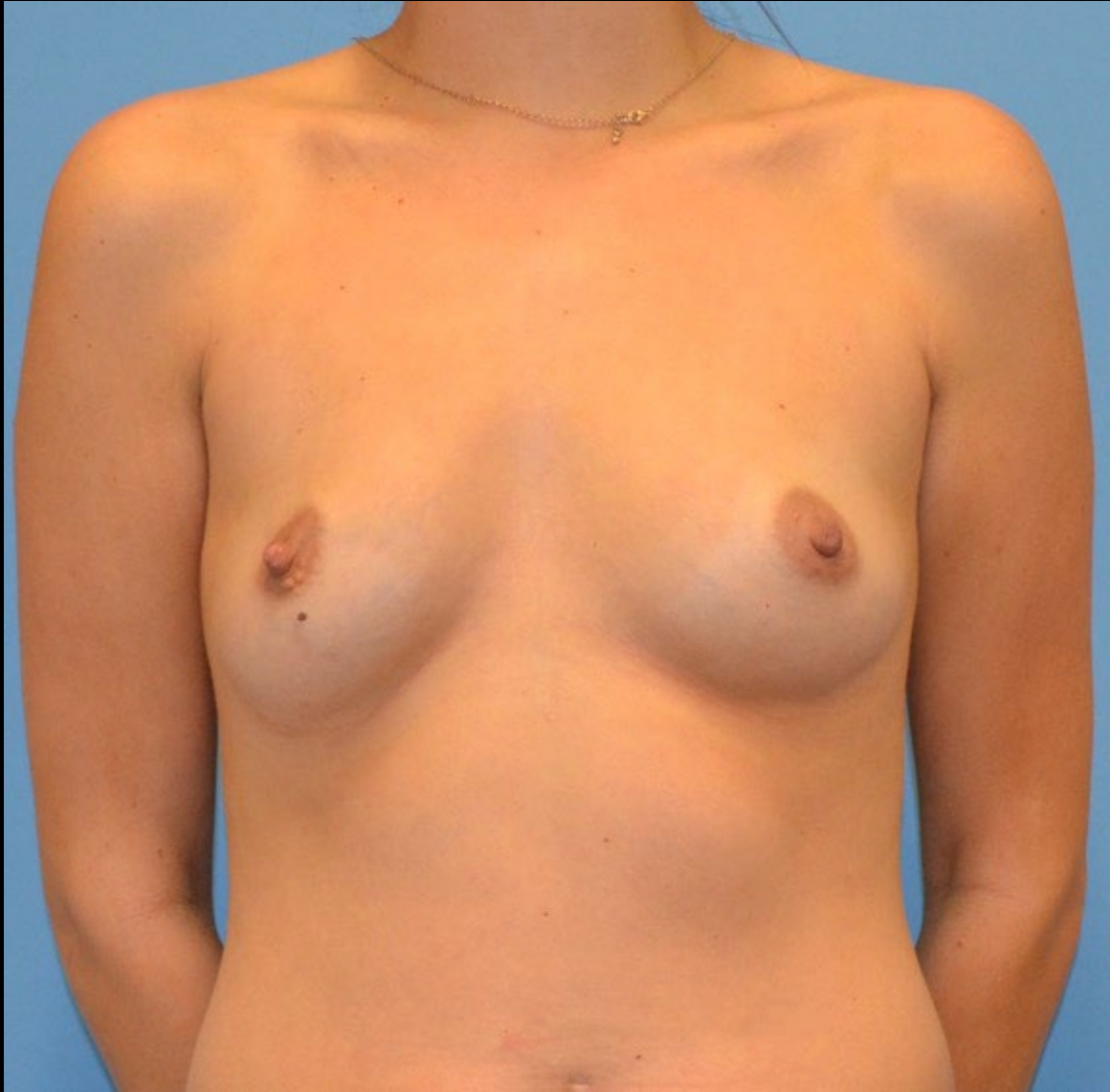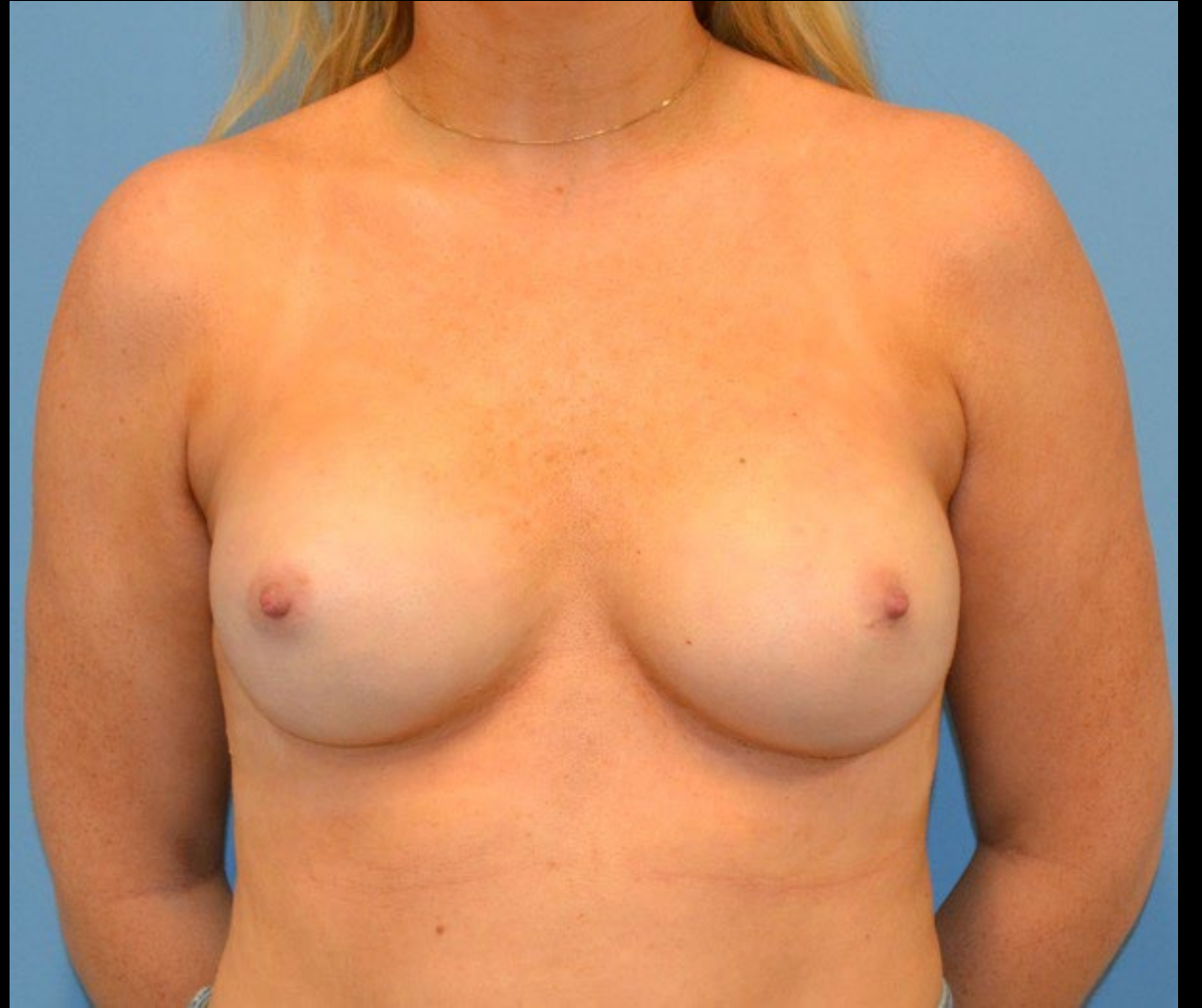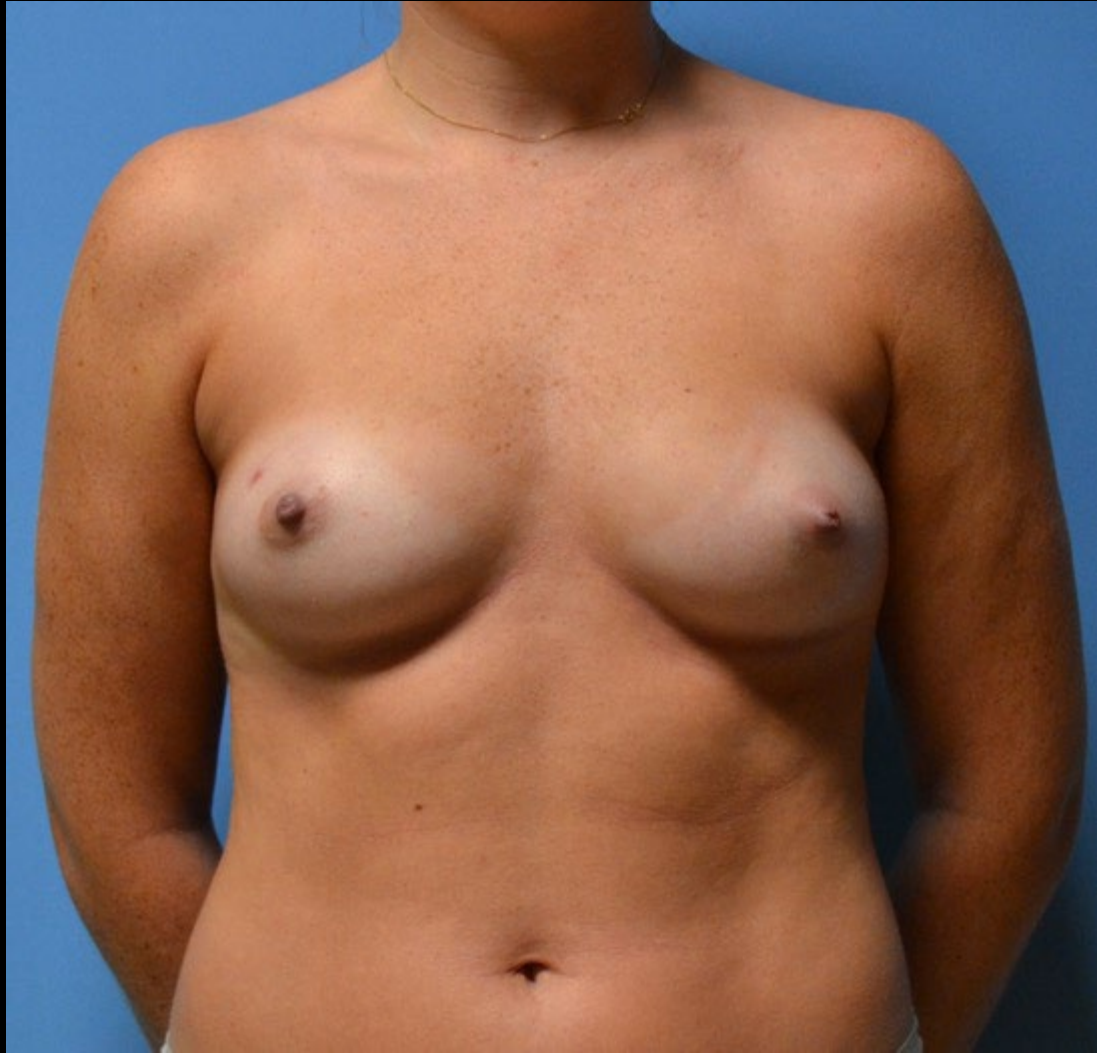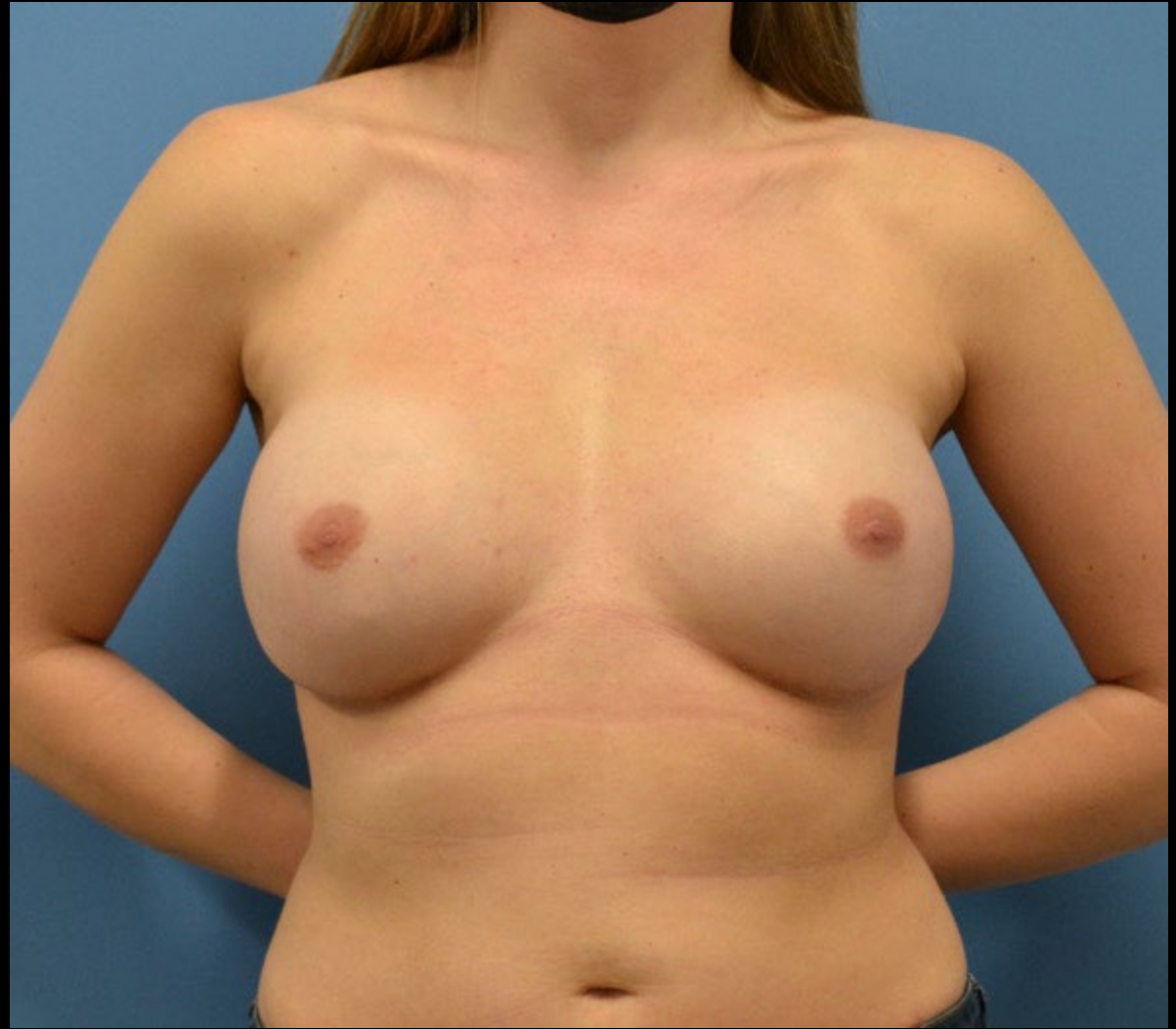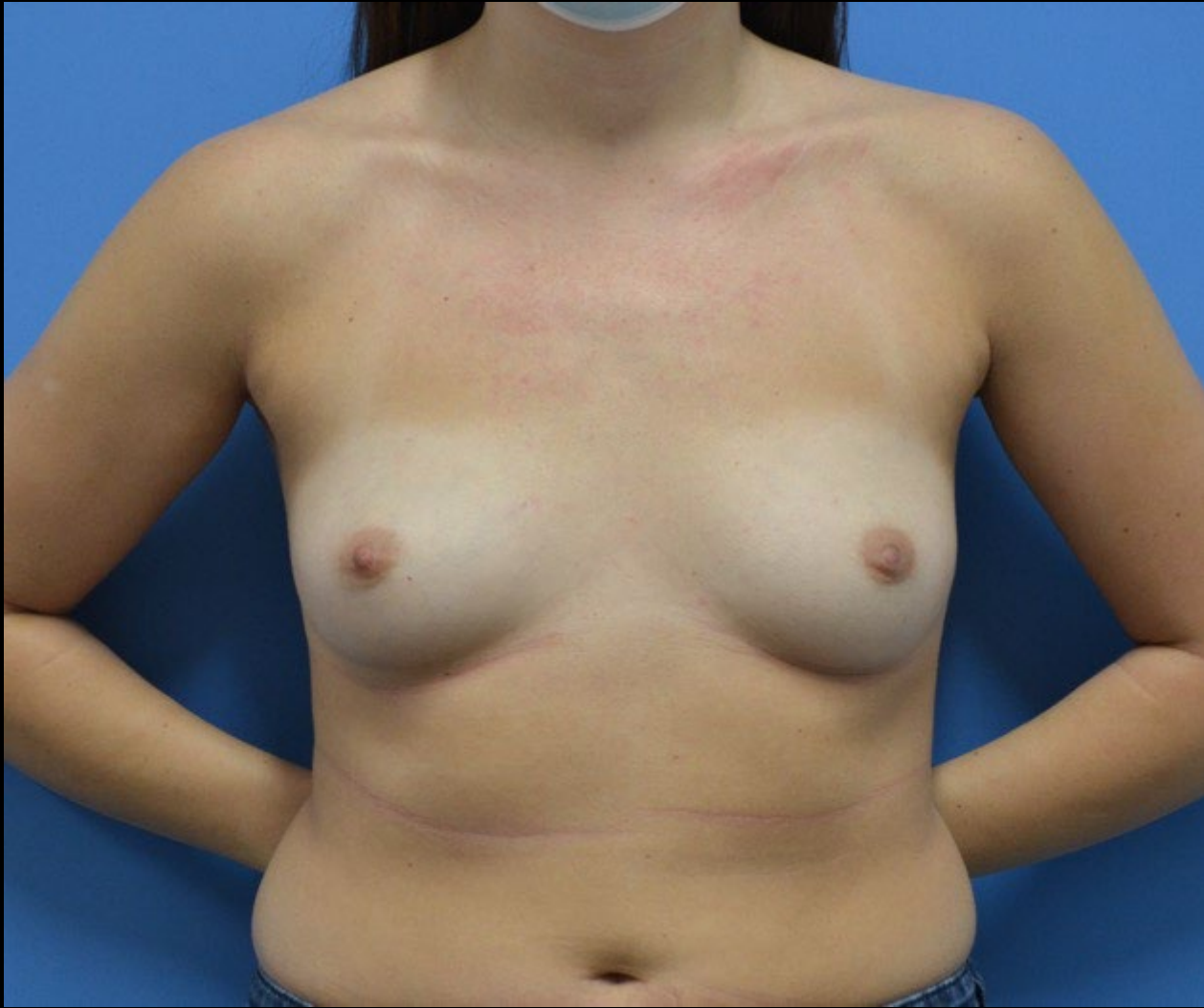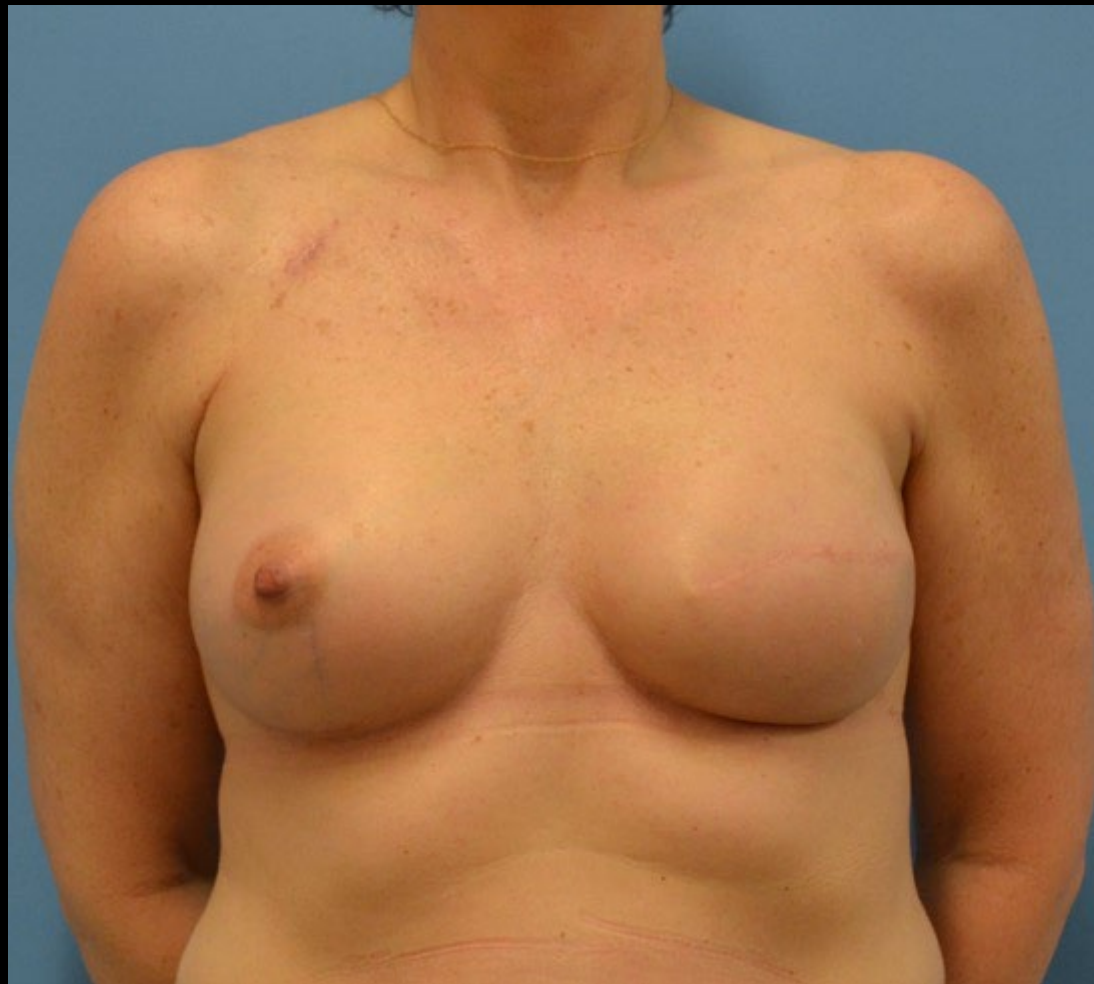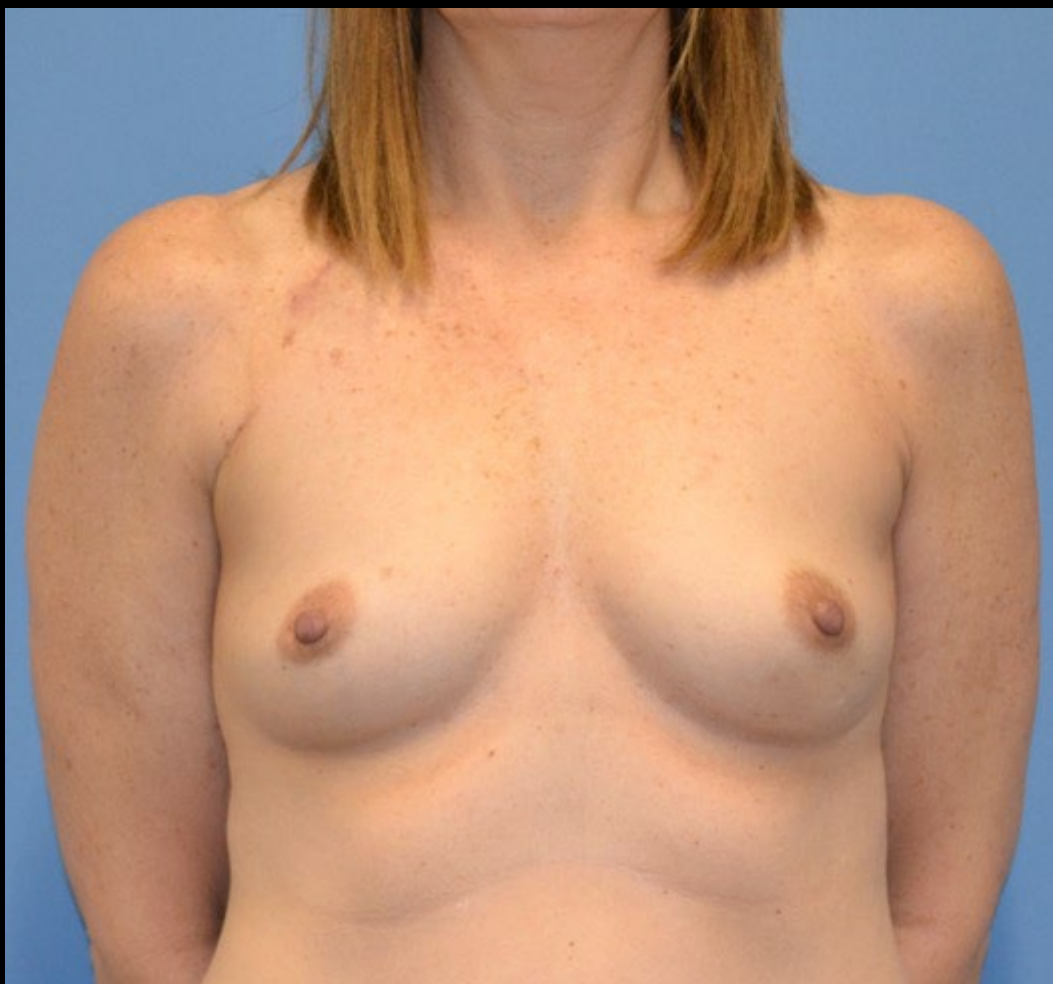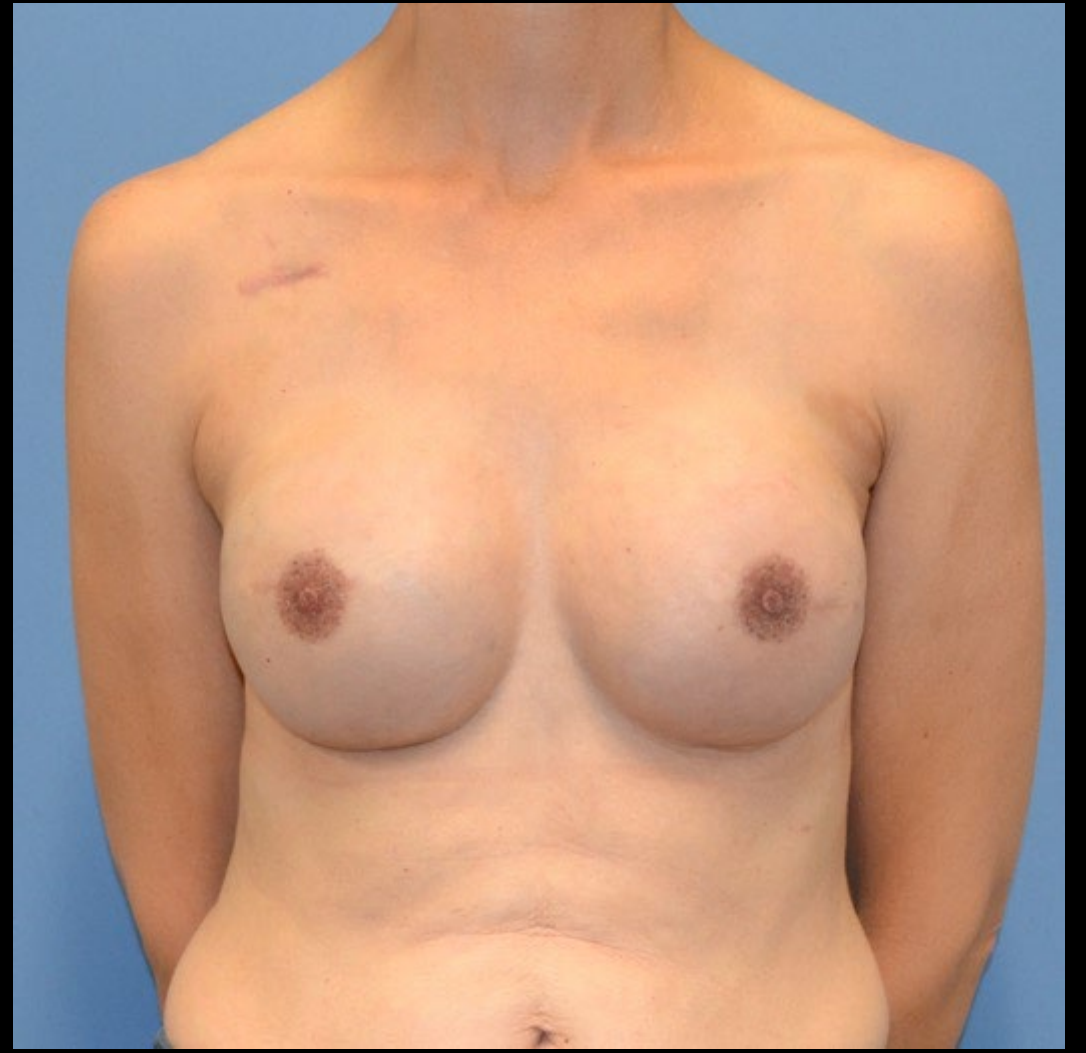












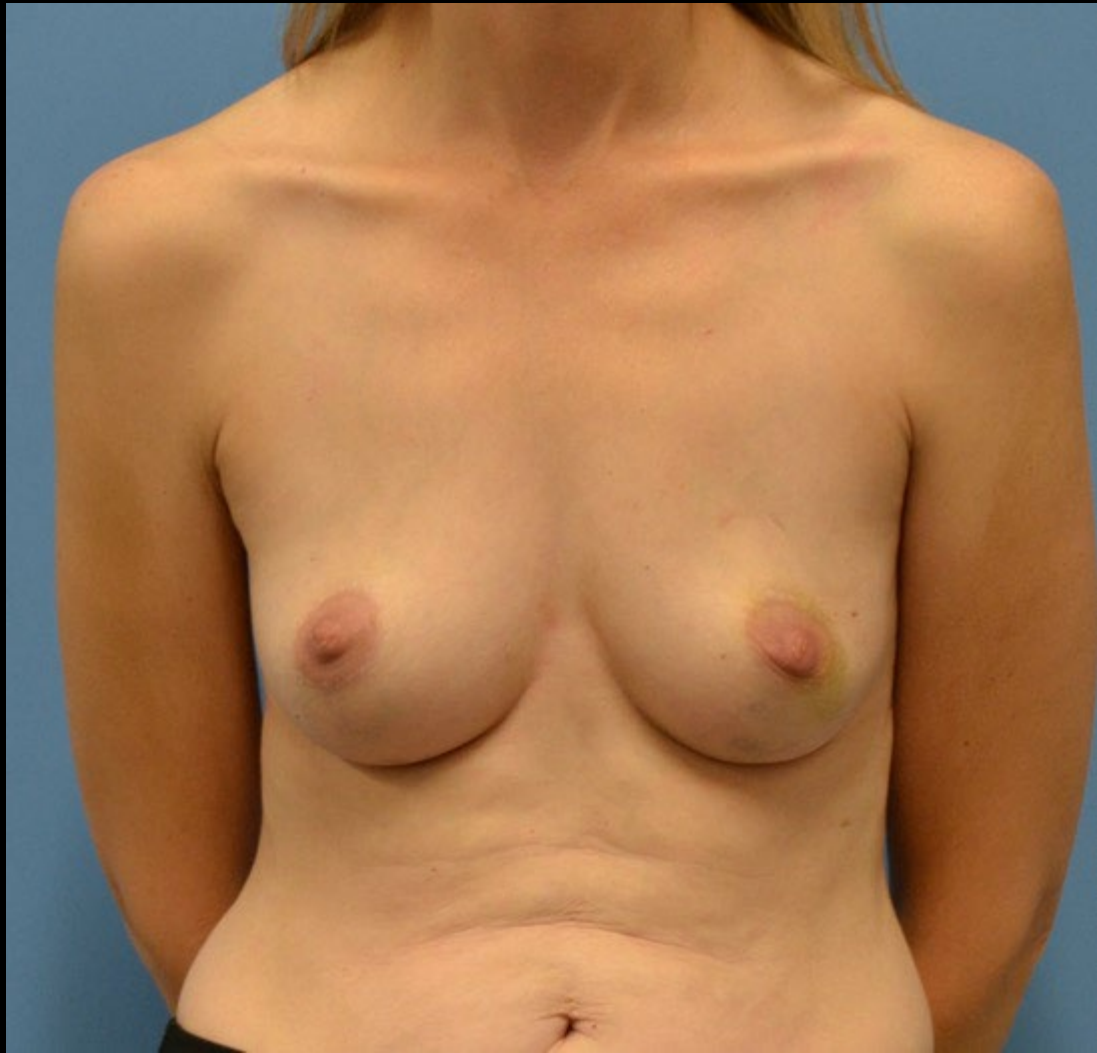# Skin Reduction Techniques

01

Wise pattern with  
dermal flap +/-  
ADM/mesh

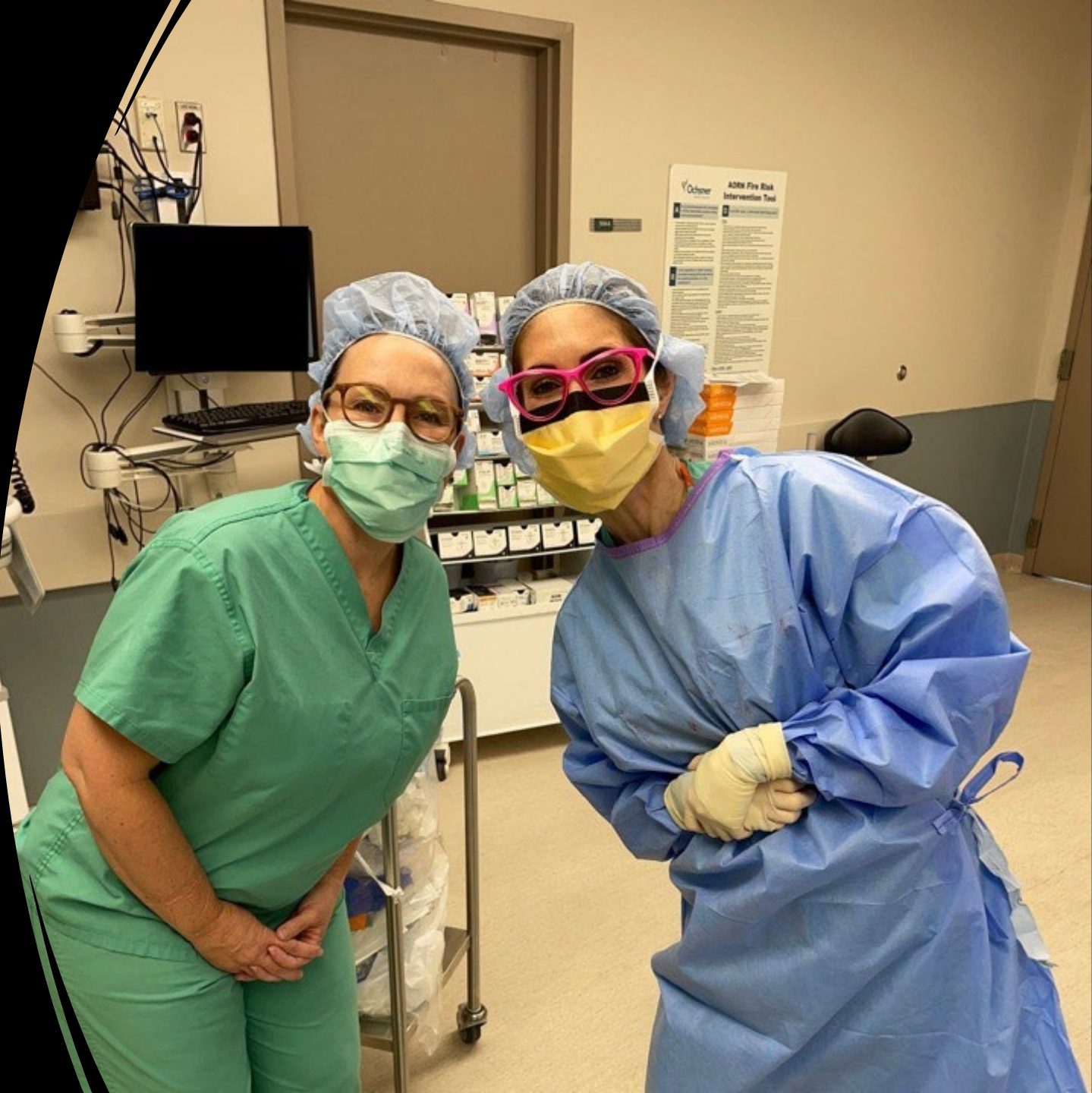02

Immediate or  
delayed skin-only  
mastopexy

03

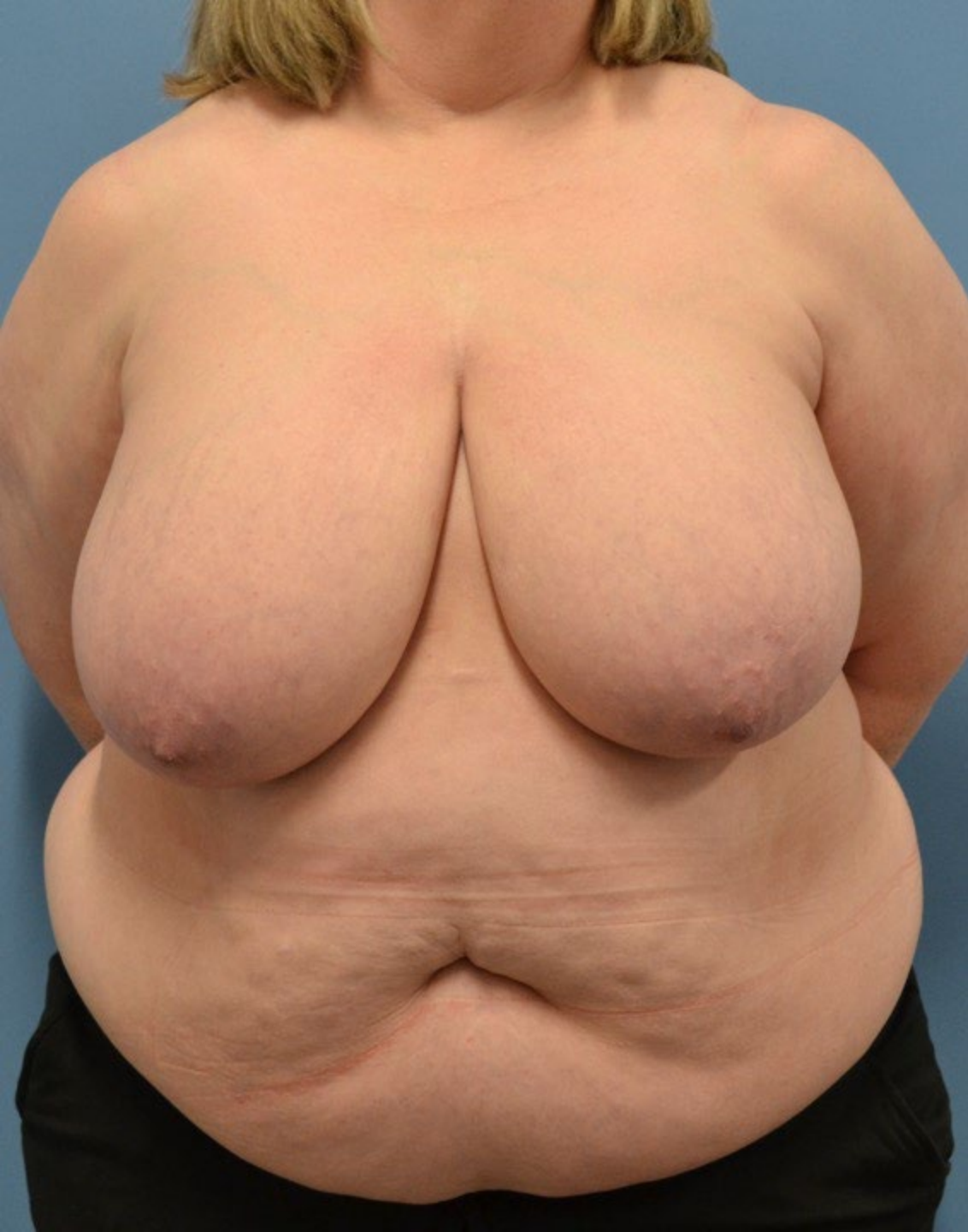Staged breast  
reduction or  
mastopexy prior to  
mastectomy

# Breast Surgery is a Partnership

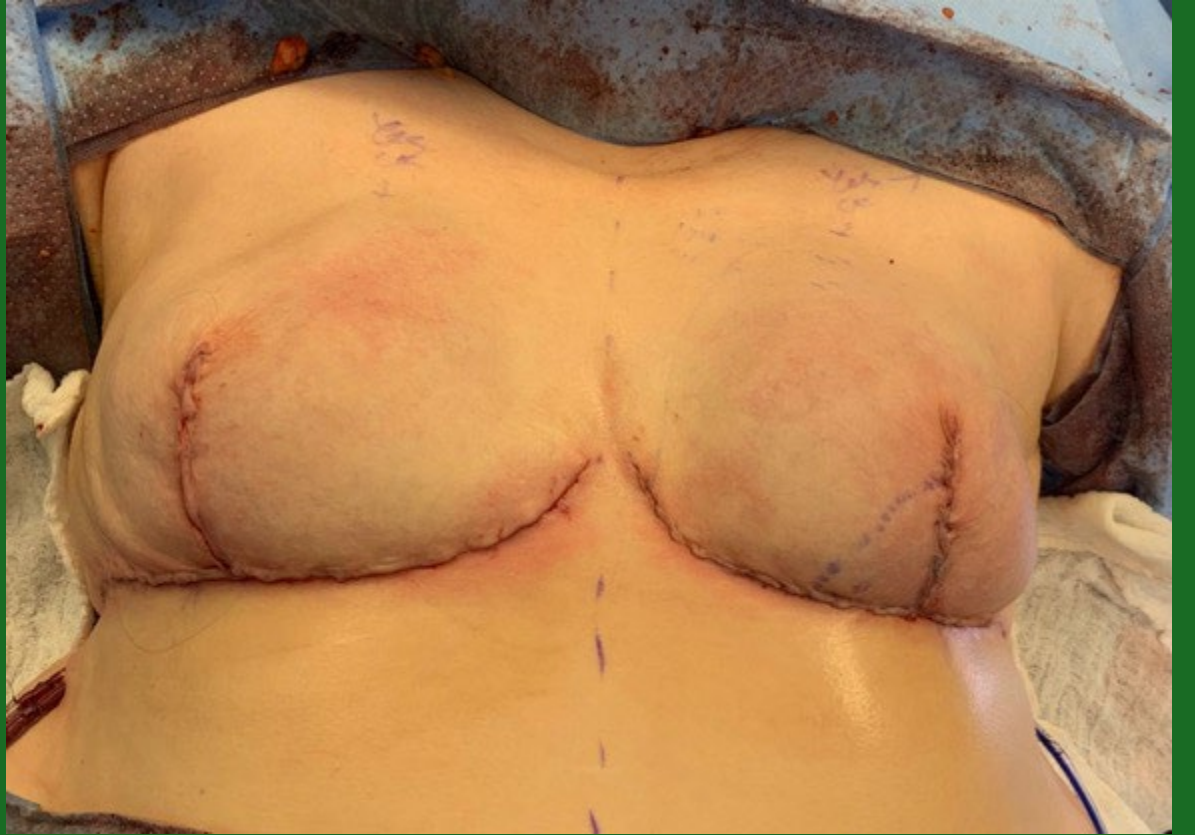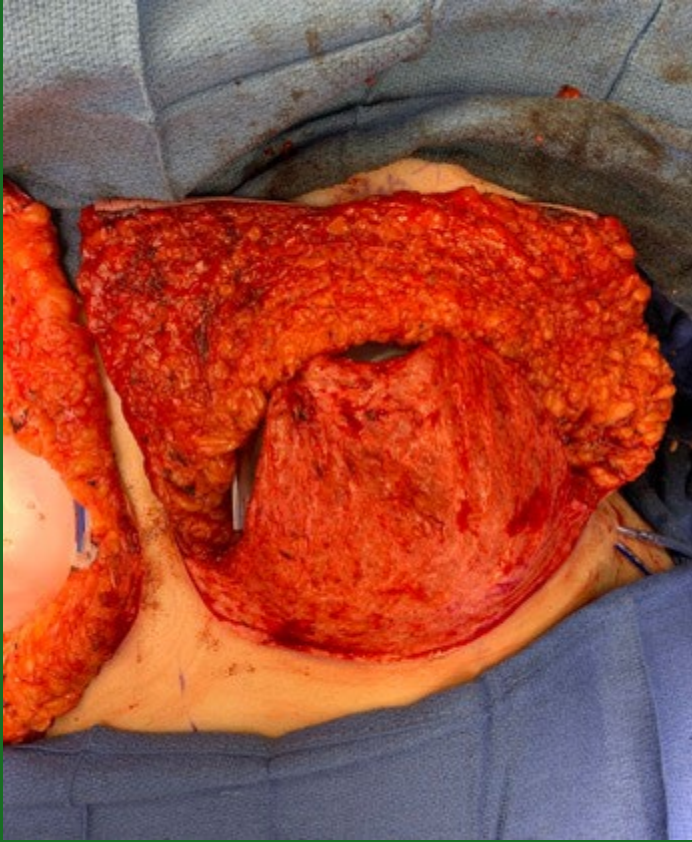


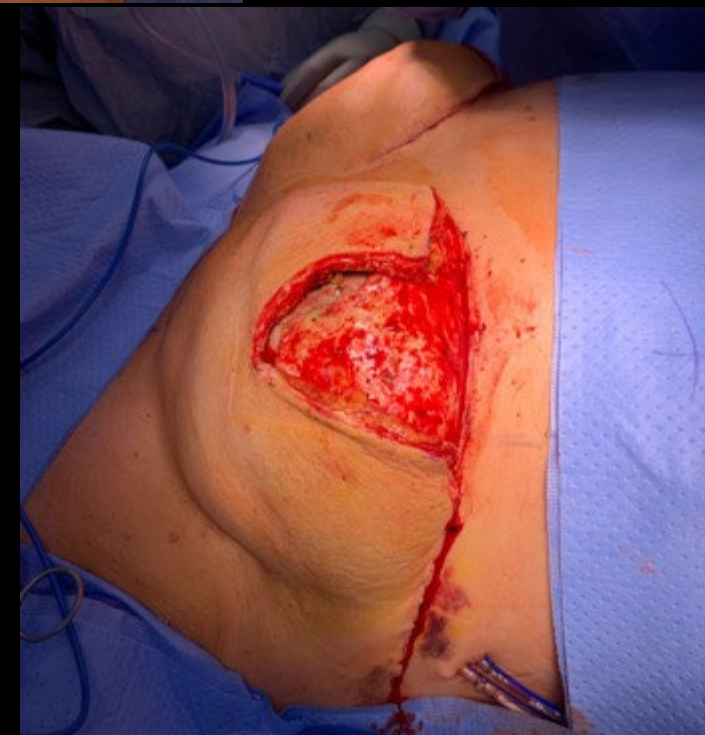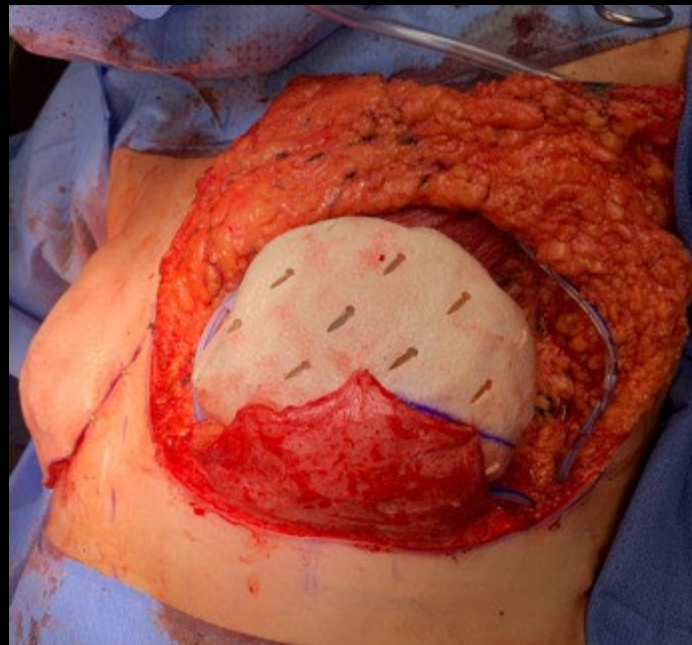
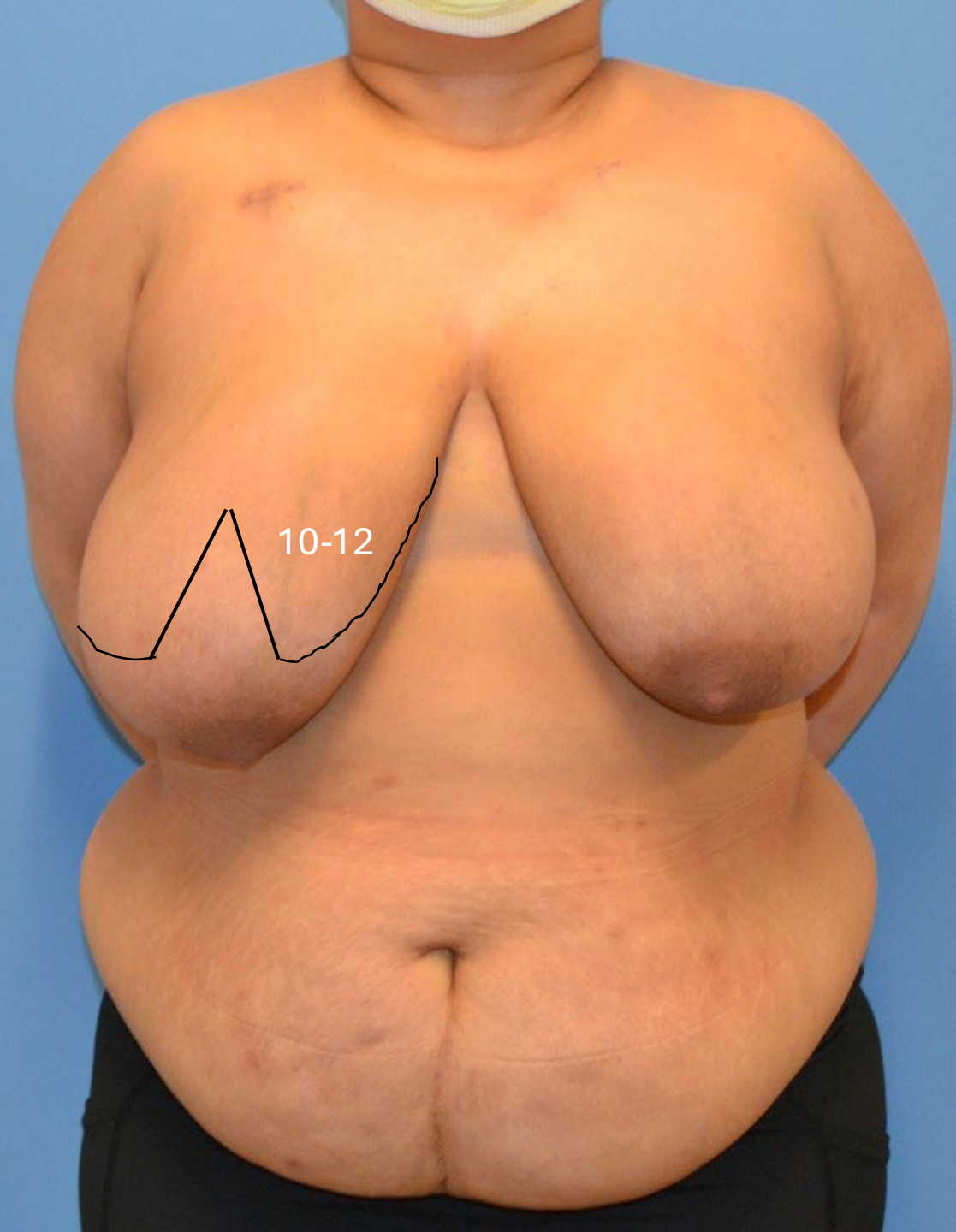# Immediate Wise Pattern Skin Excision

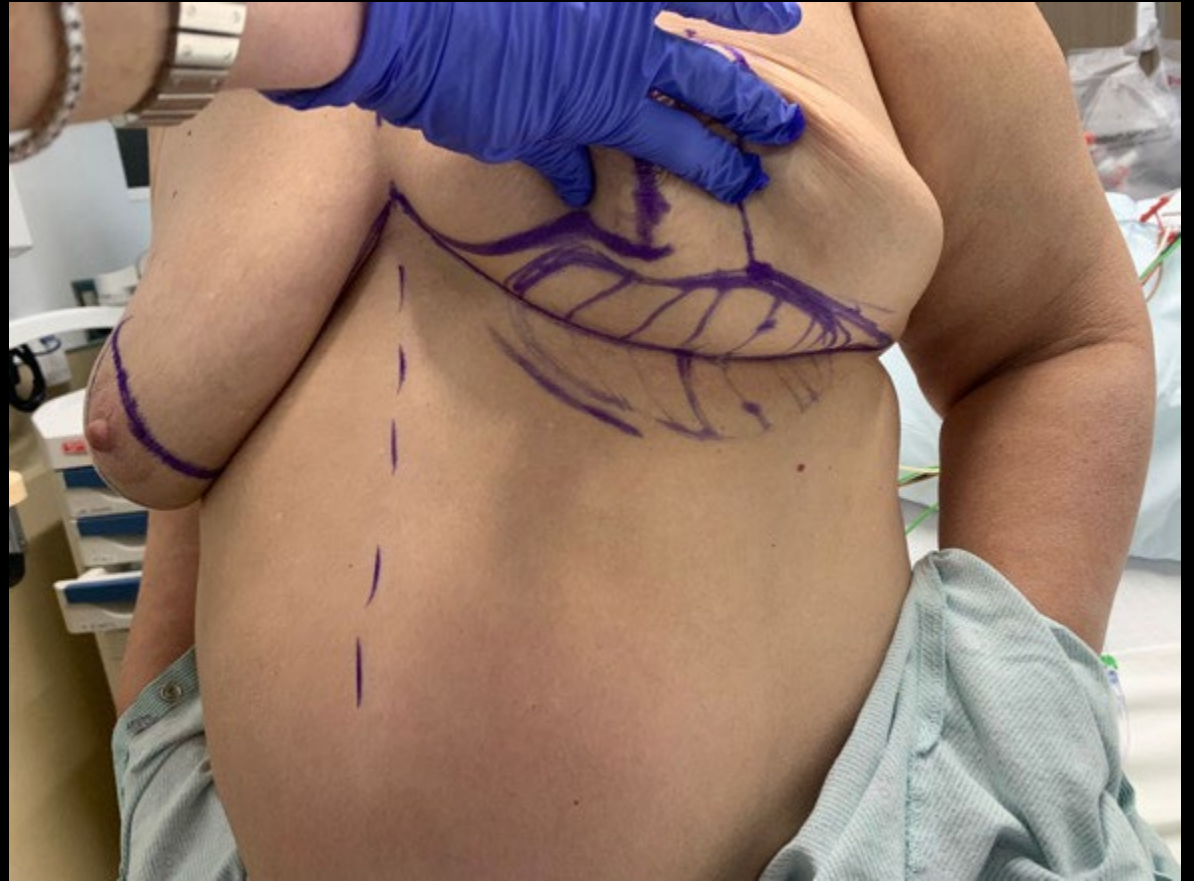
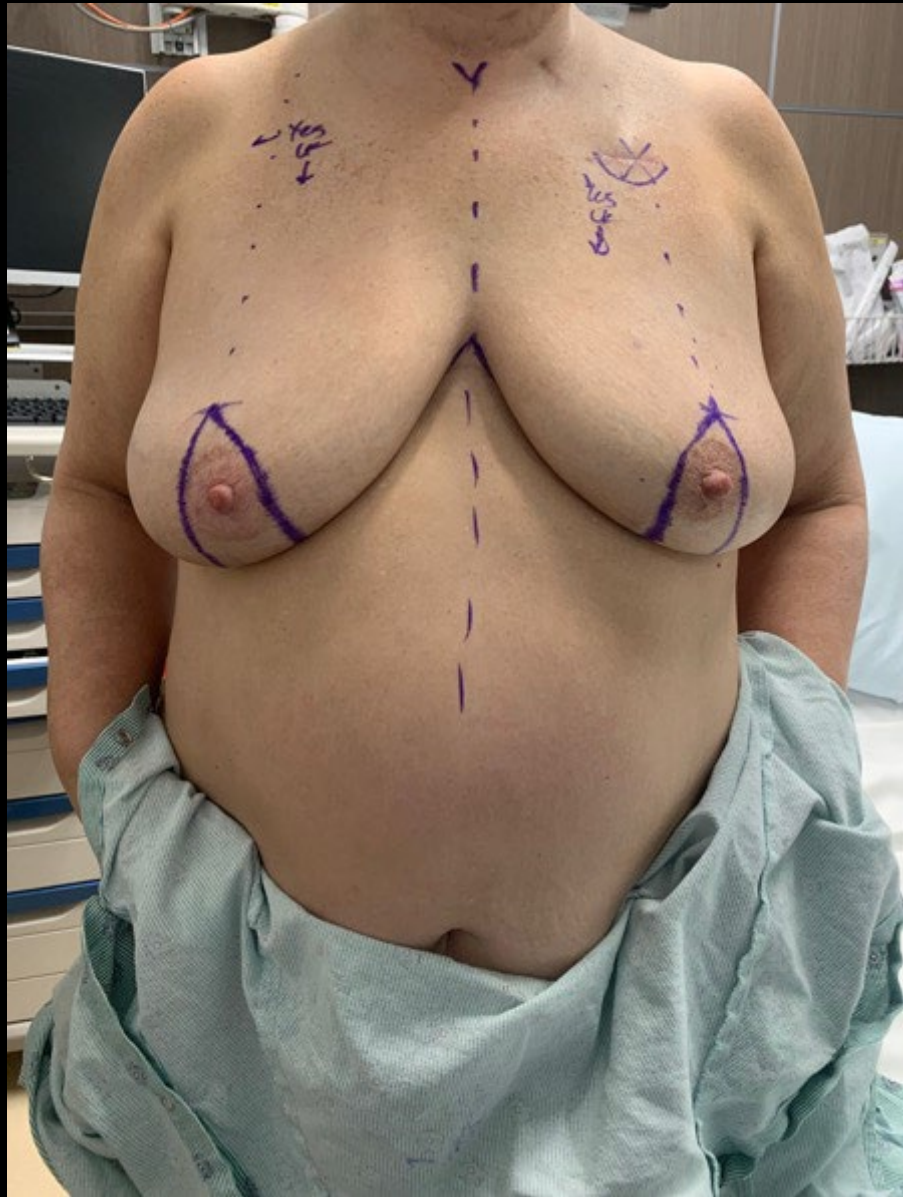


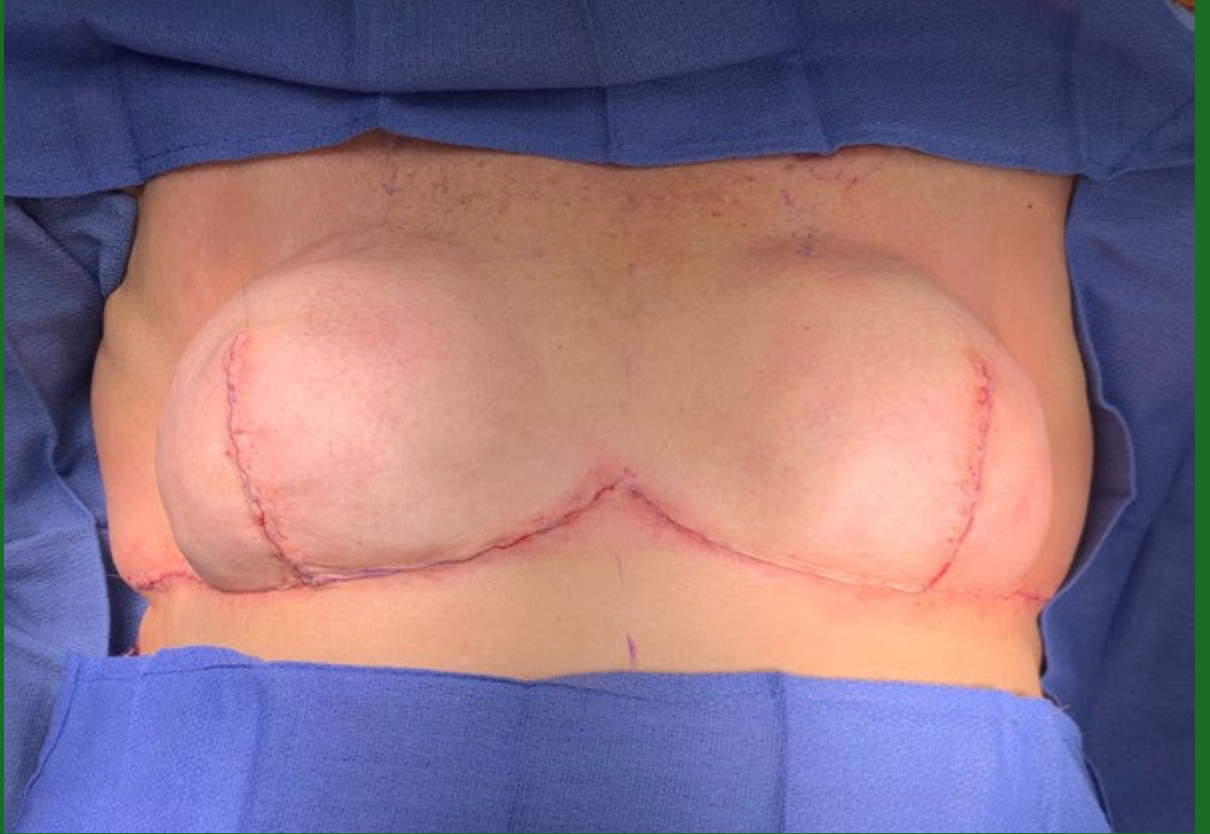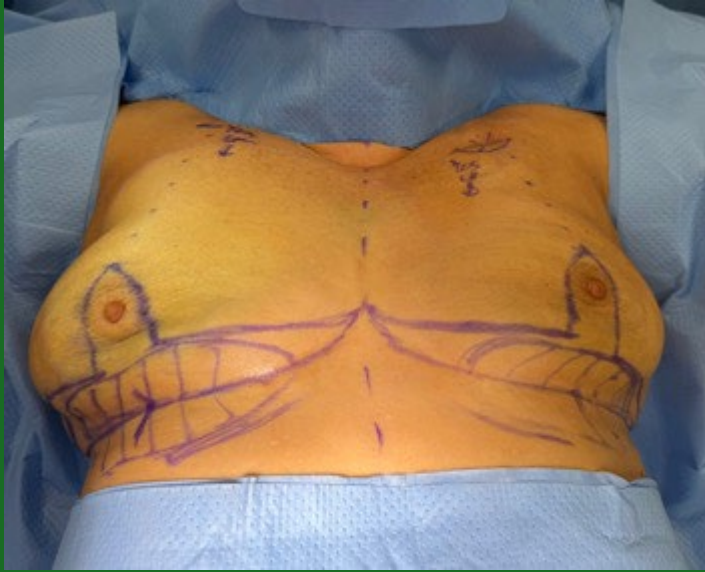- BMI 43, BSSM
- Immediate TE reconstruction
- Wise pattern mastectomy with dermal flap
- Weight loss to BMI 35
- Delayed DIEP reconstruction





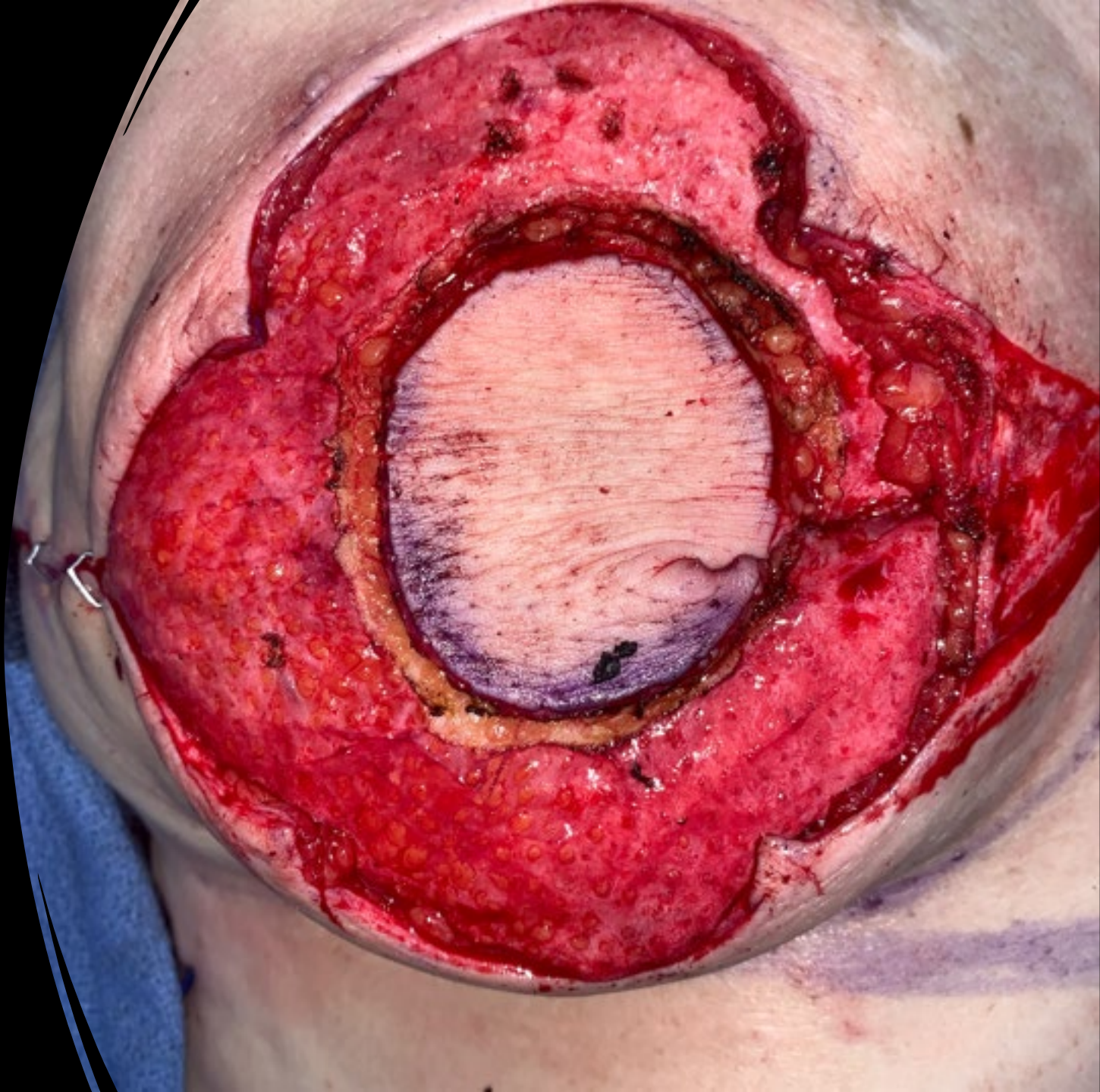



# Insetting a Flap

---

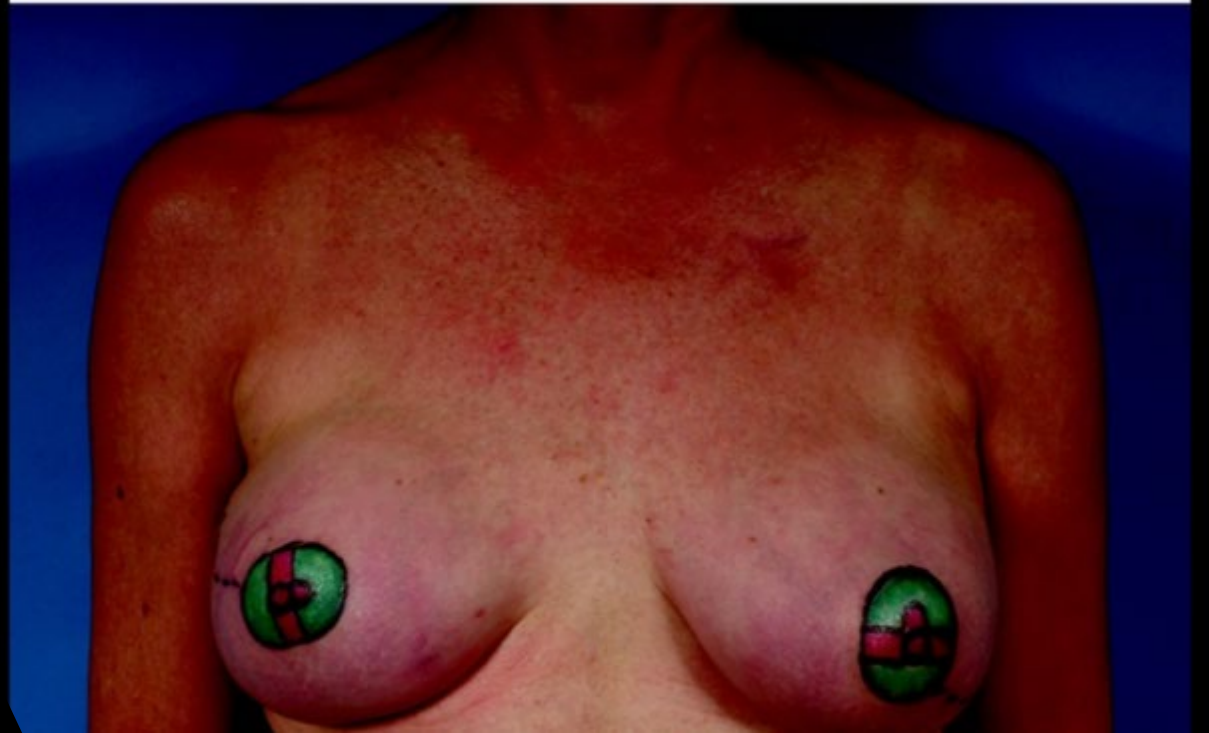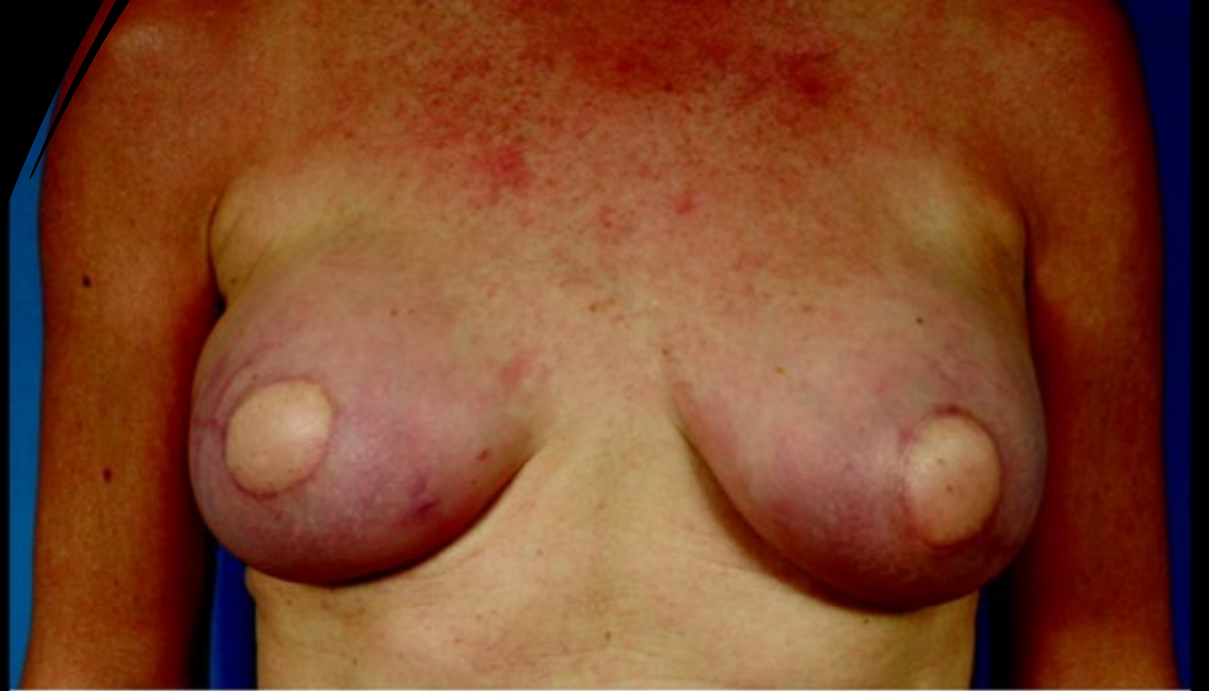- Use a circular skin island
- Hammond nipple at second stage
- Ultimate result looks like a breast reduction

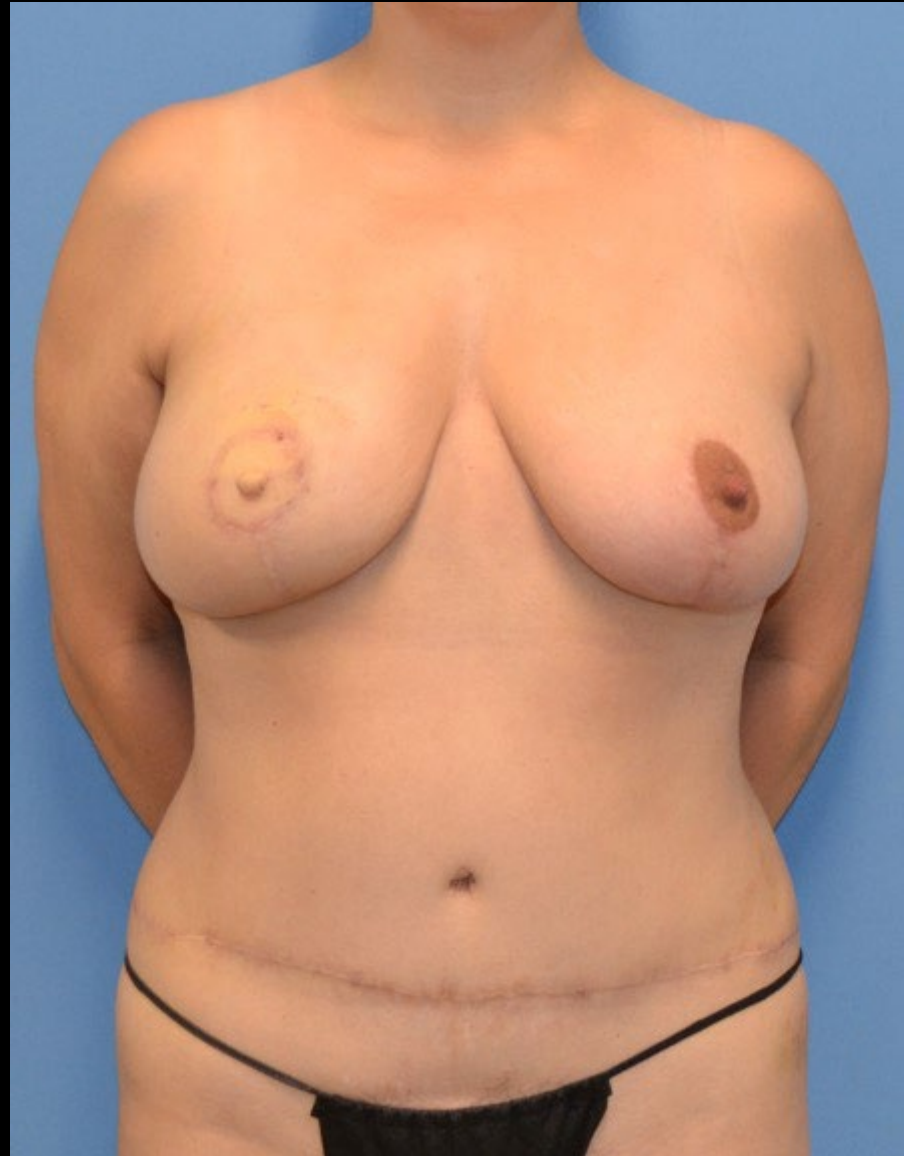
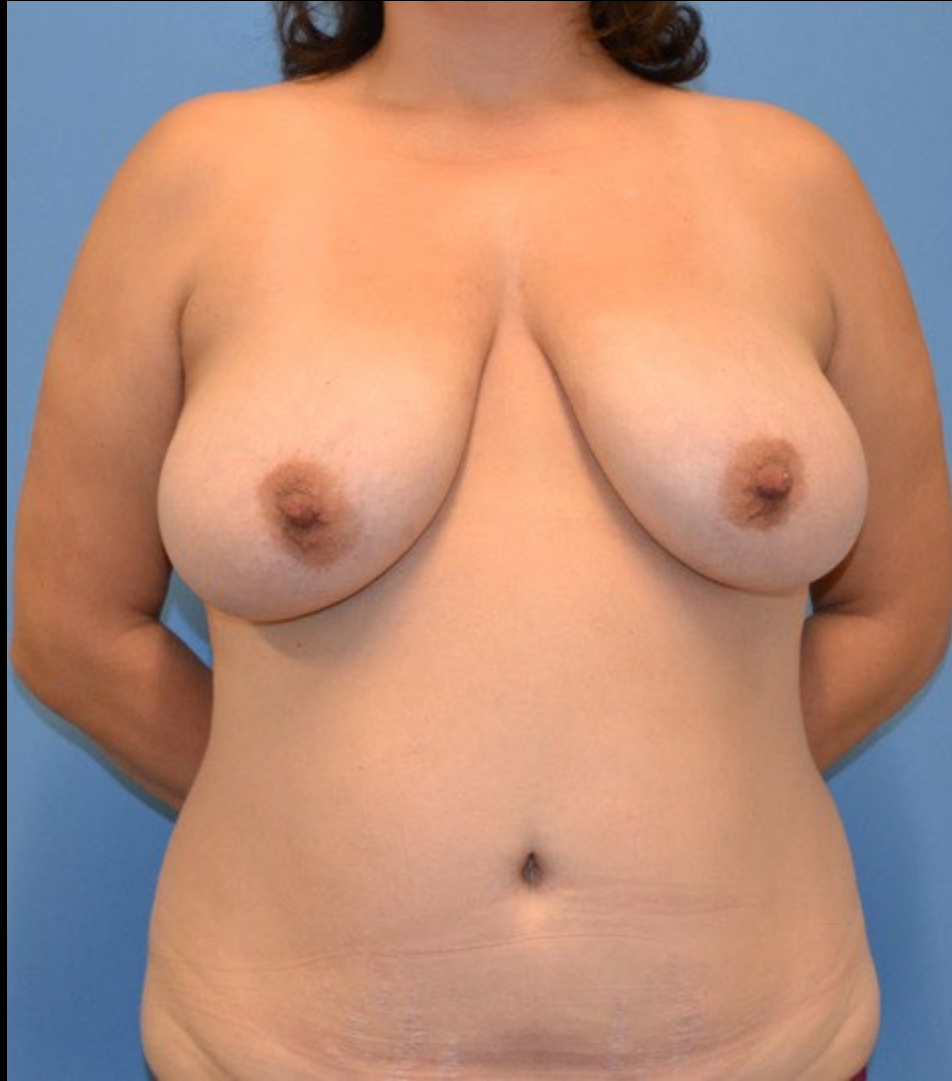
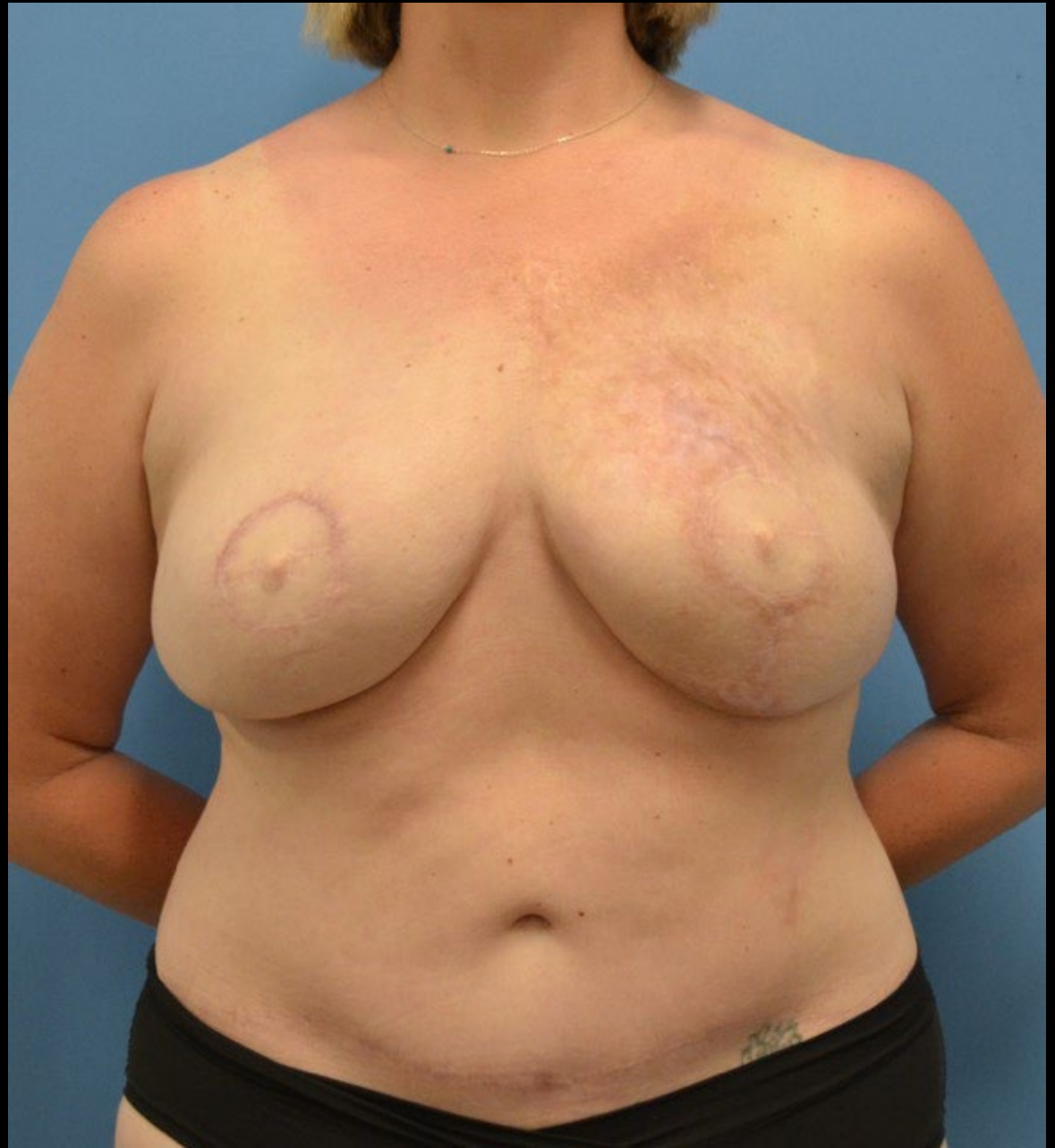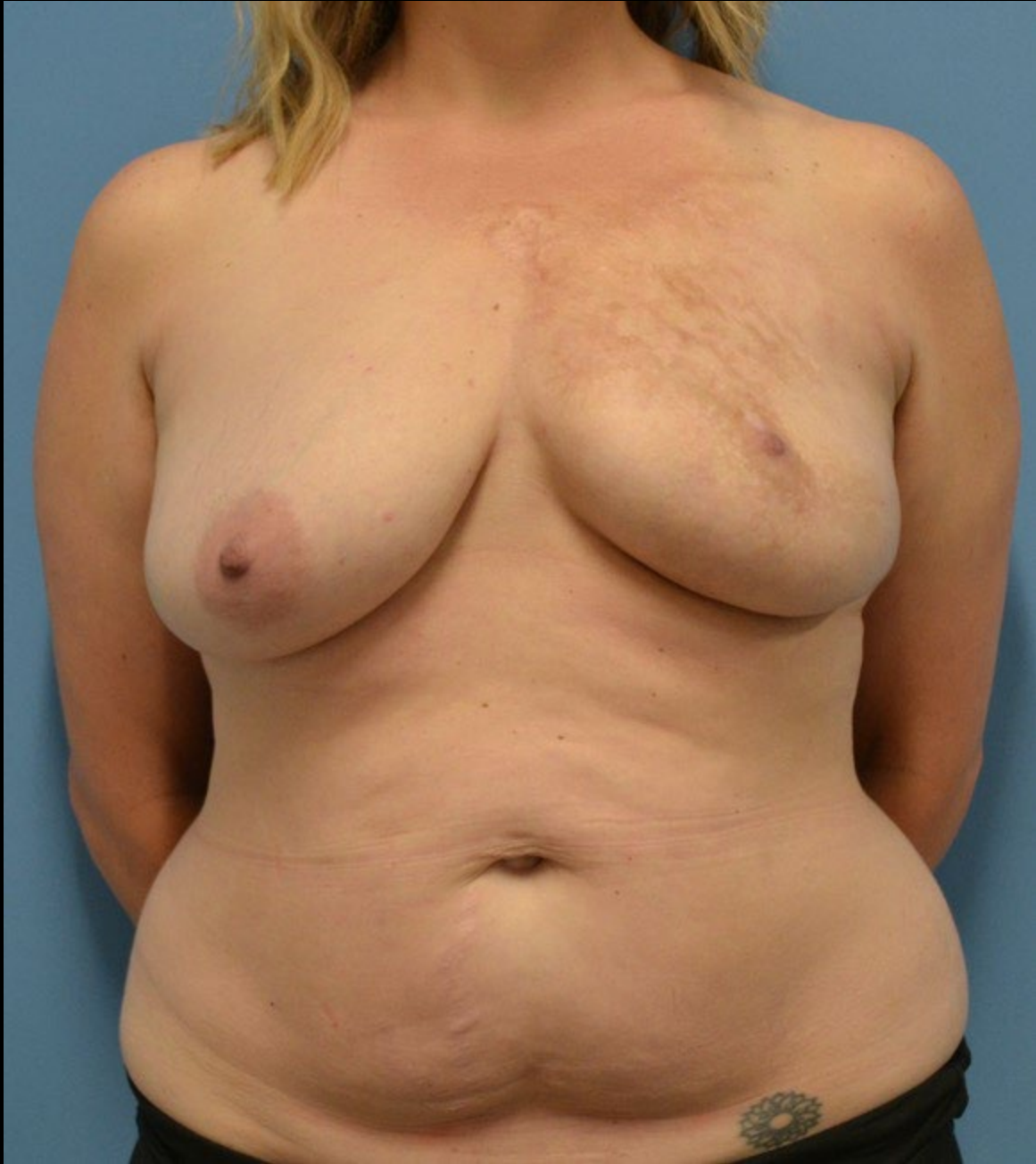# Nipple Reconstruction Technique with Circular Skin Island

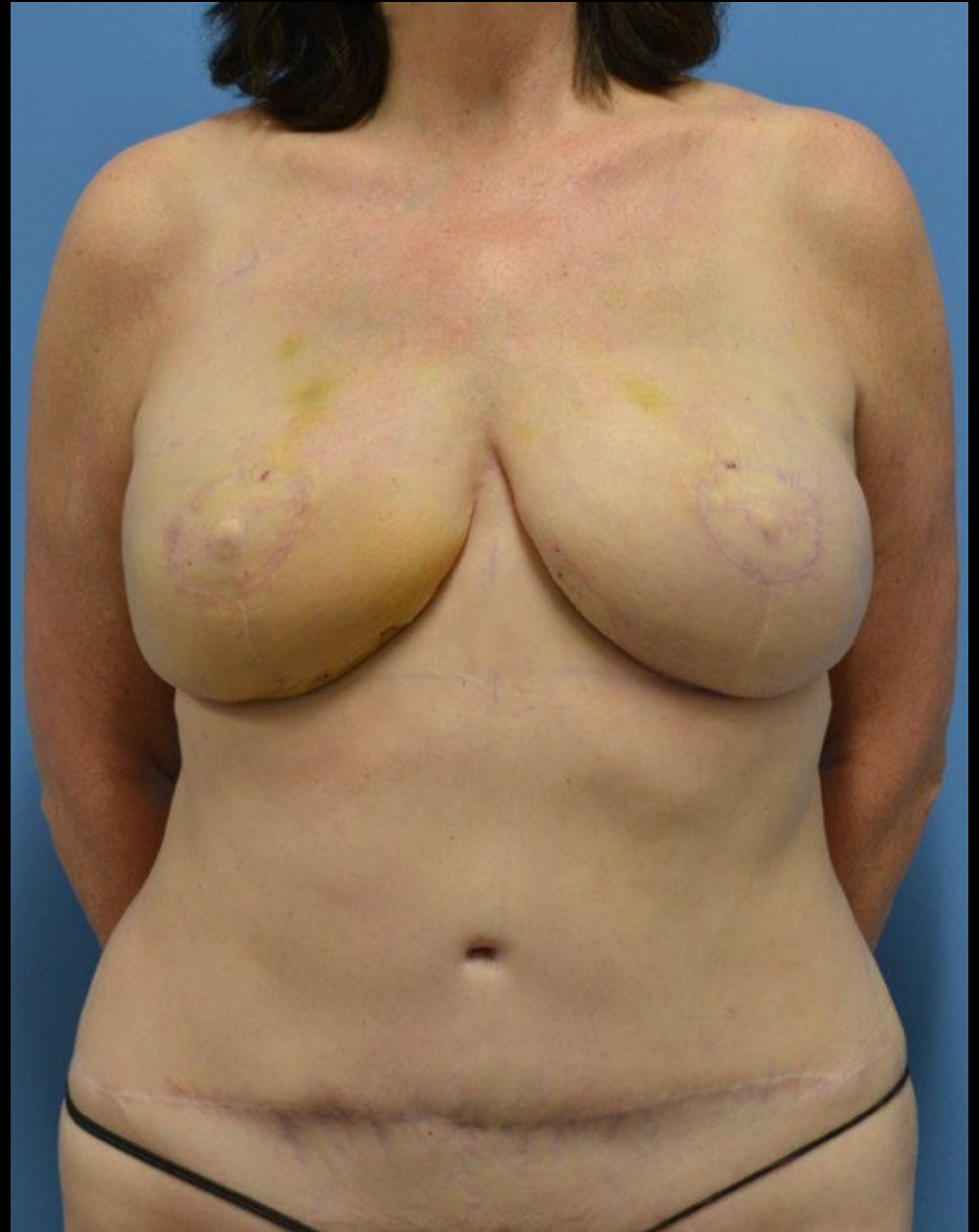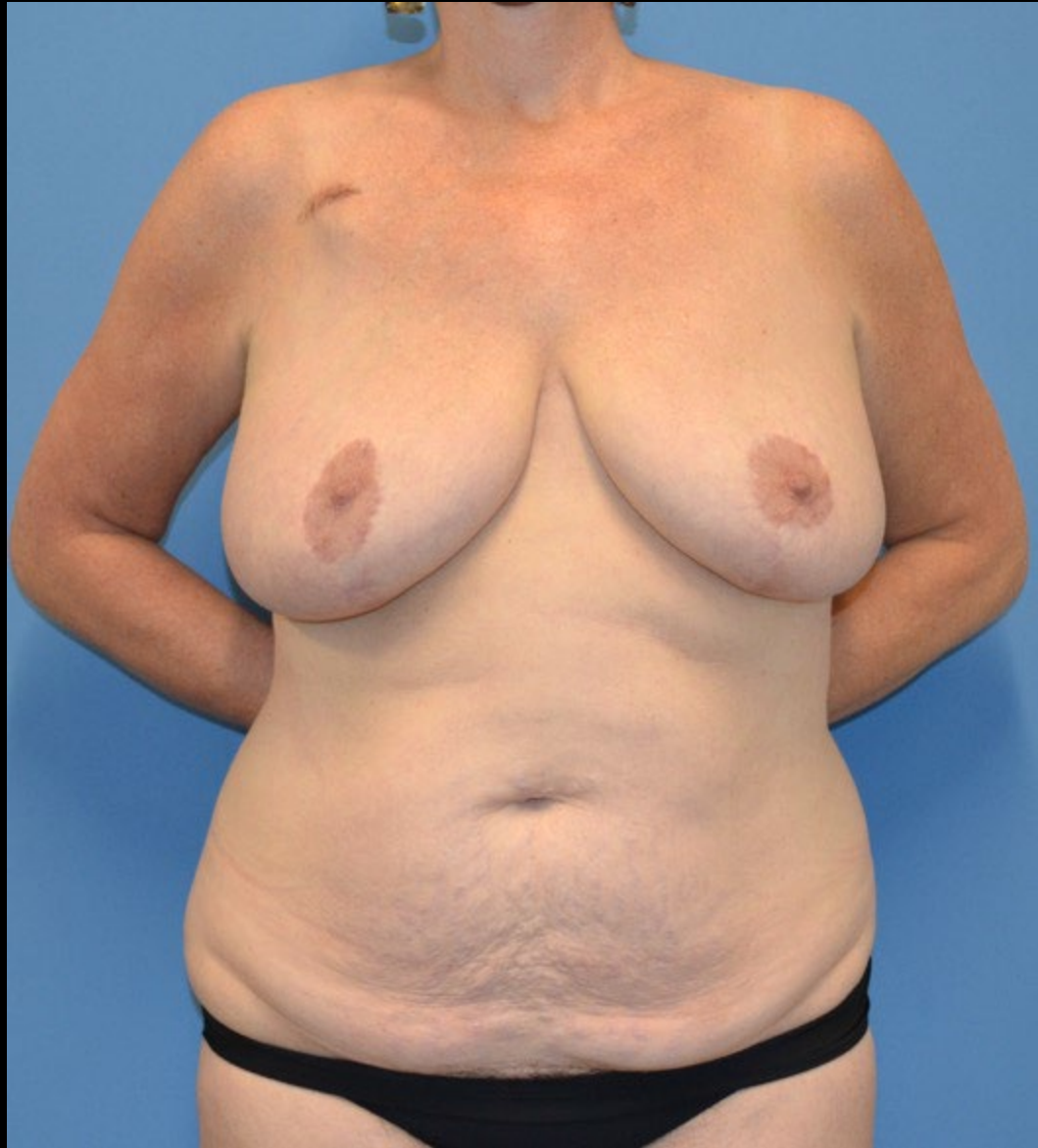---

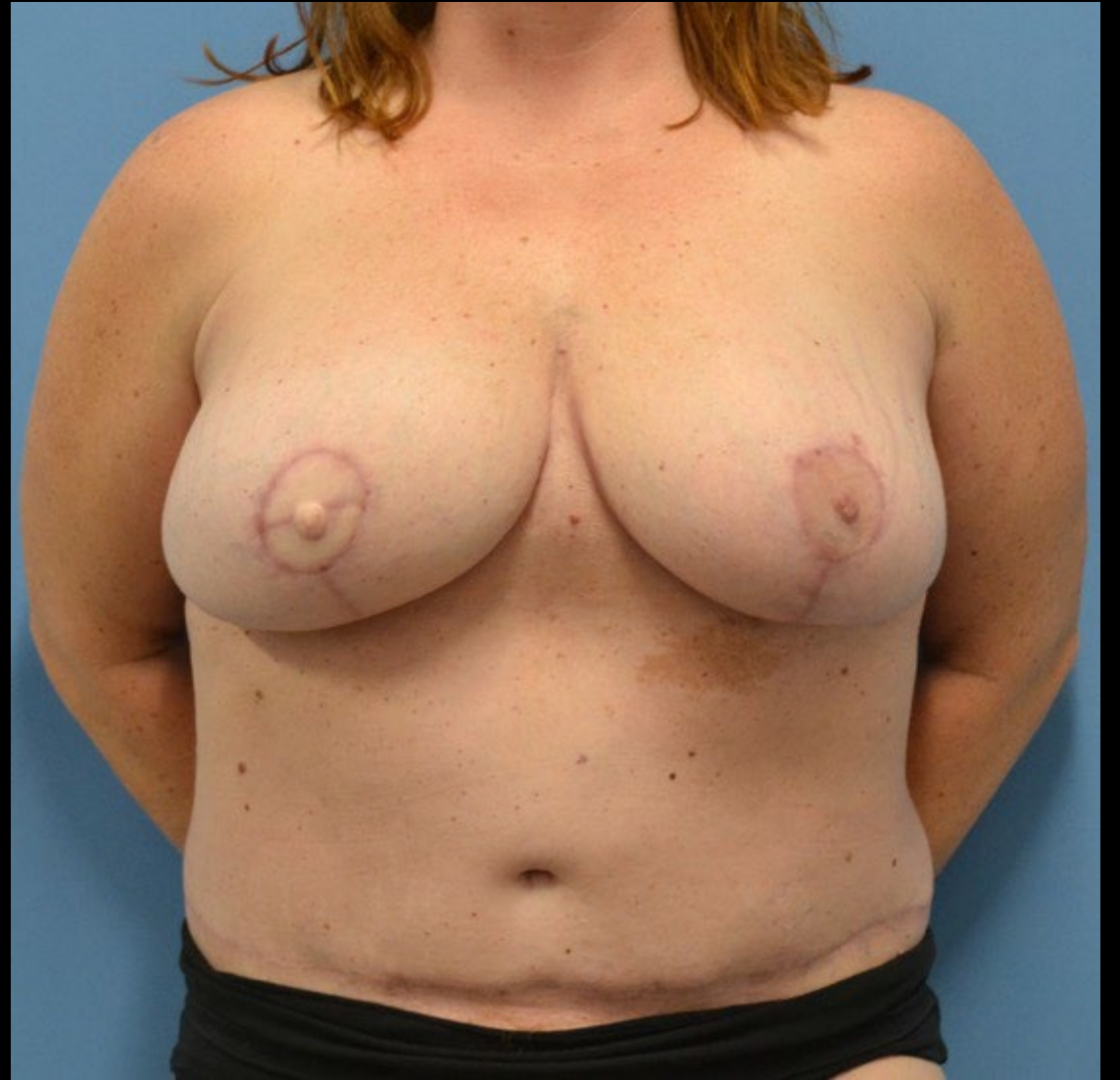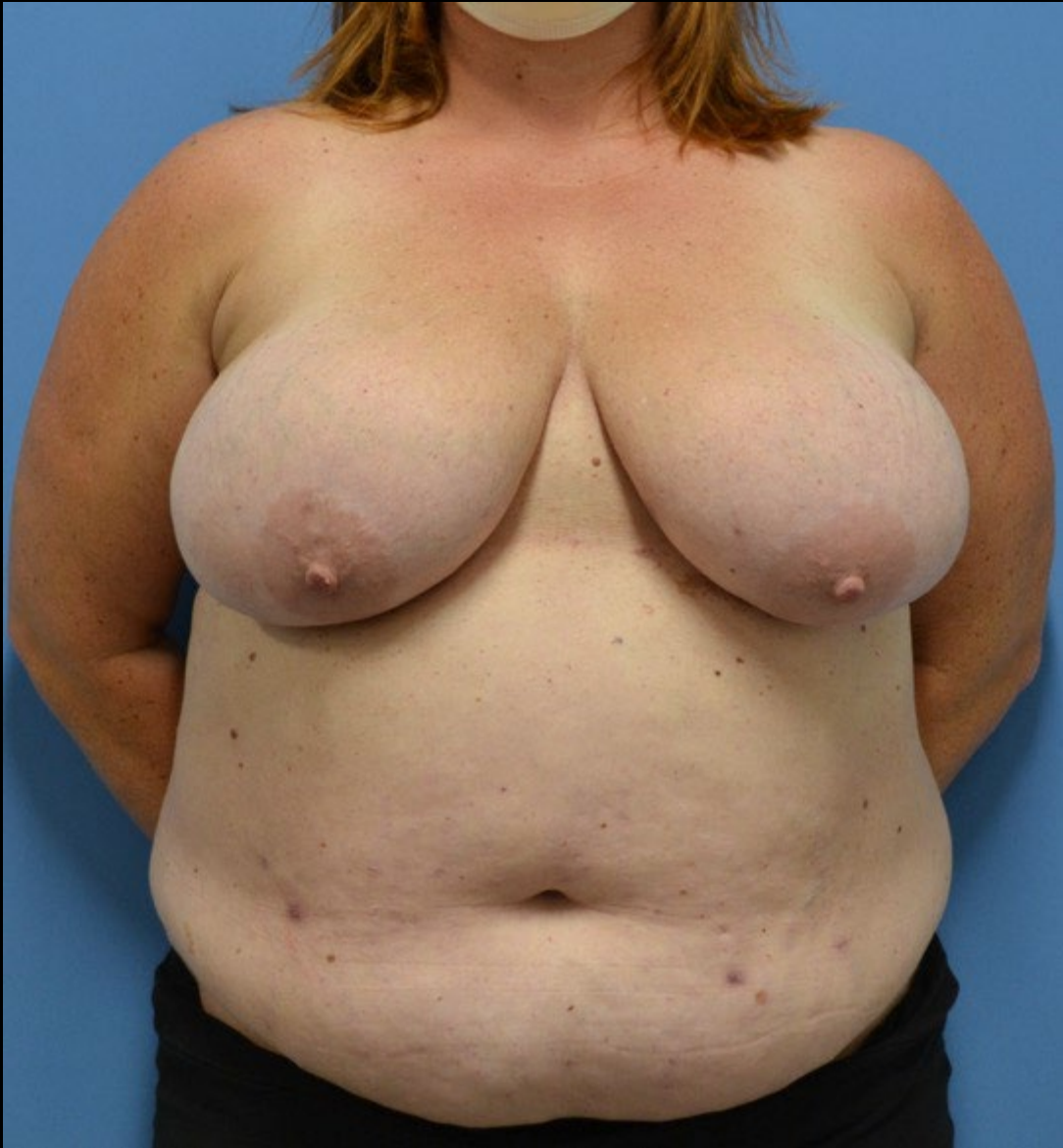- Dennis Hammond
- Latissimus Dorsi Breast Reconstruction
- Plastic and Reconstructive Surgery 124(4):1055-1063, October 2009.

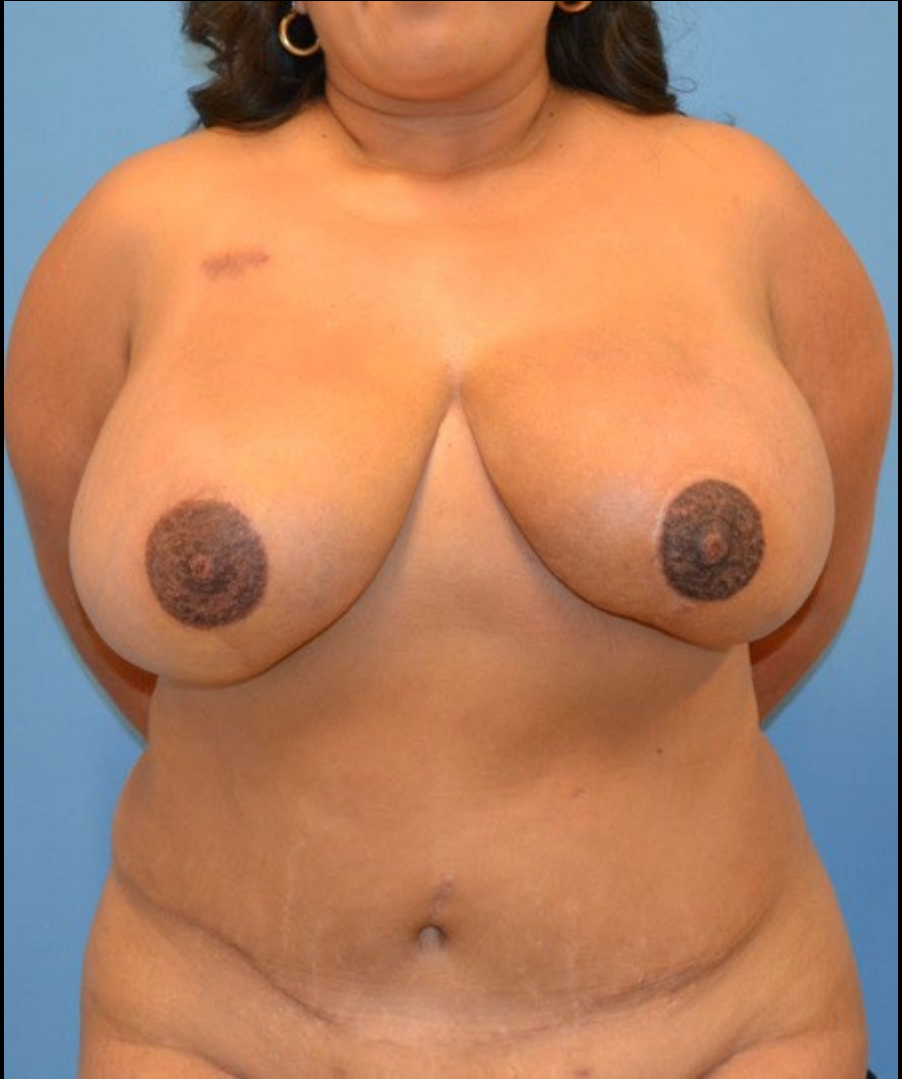
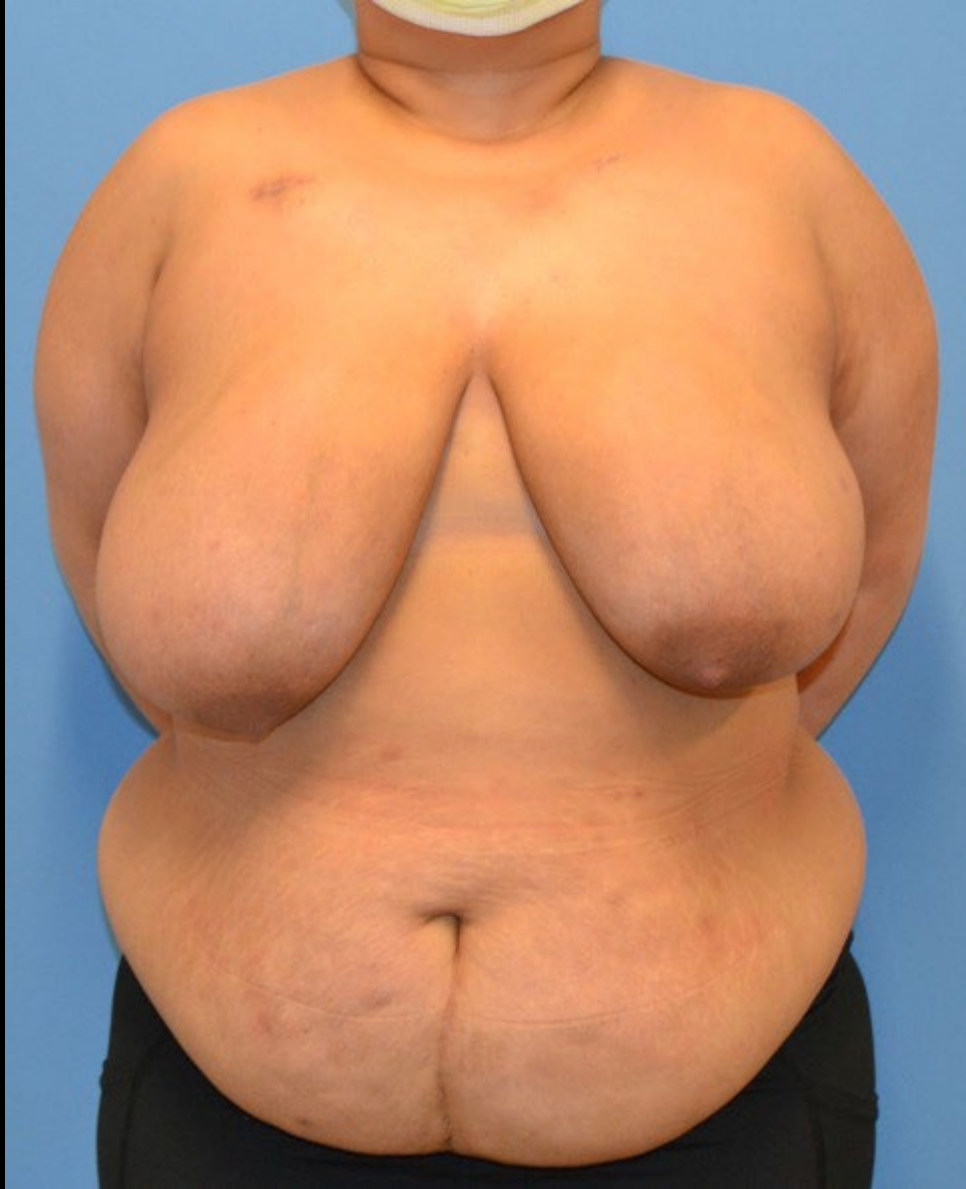


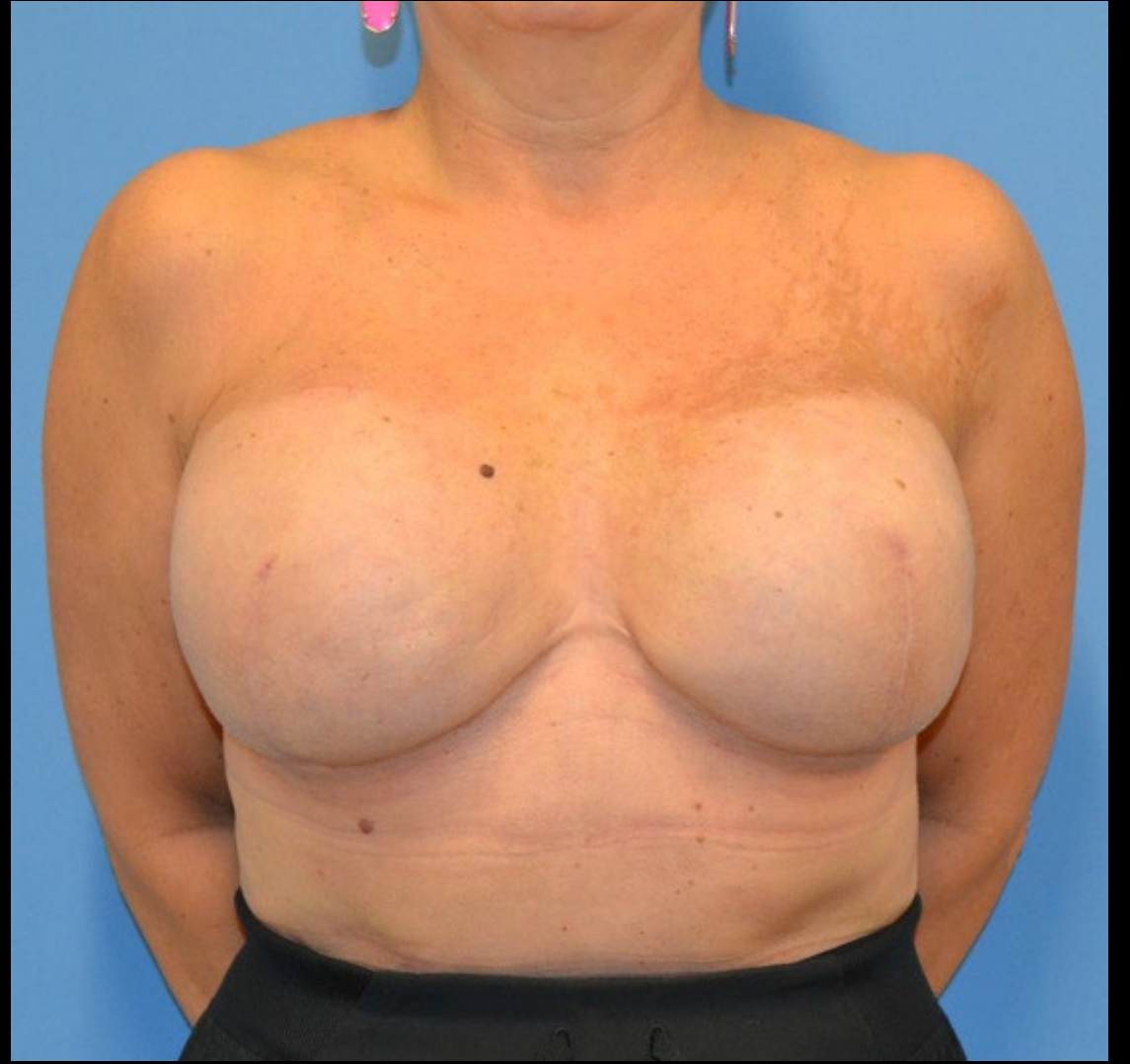
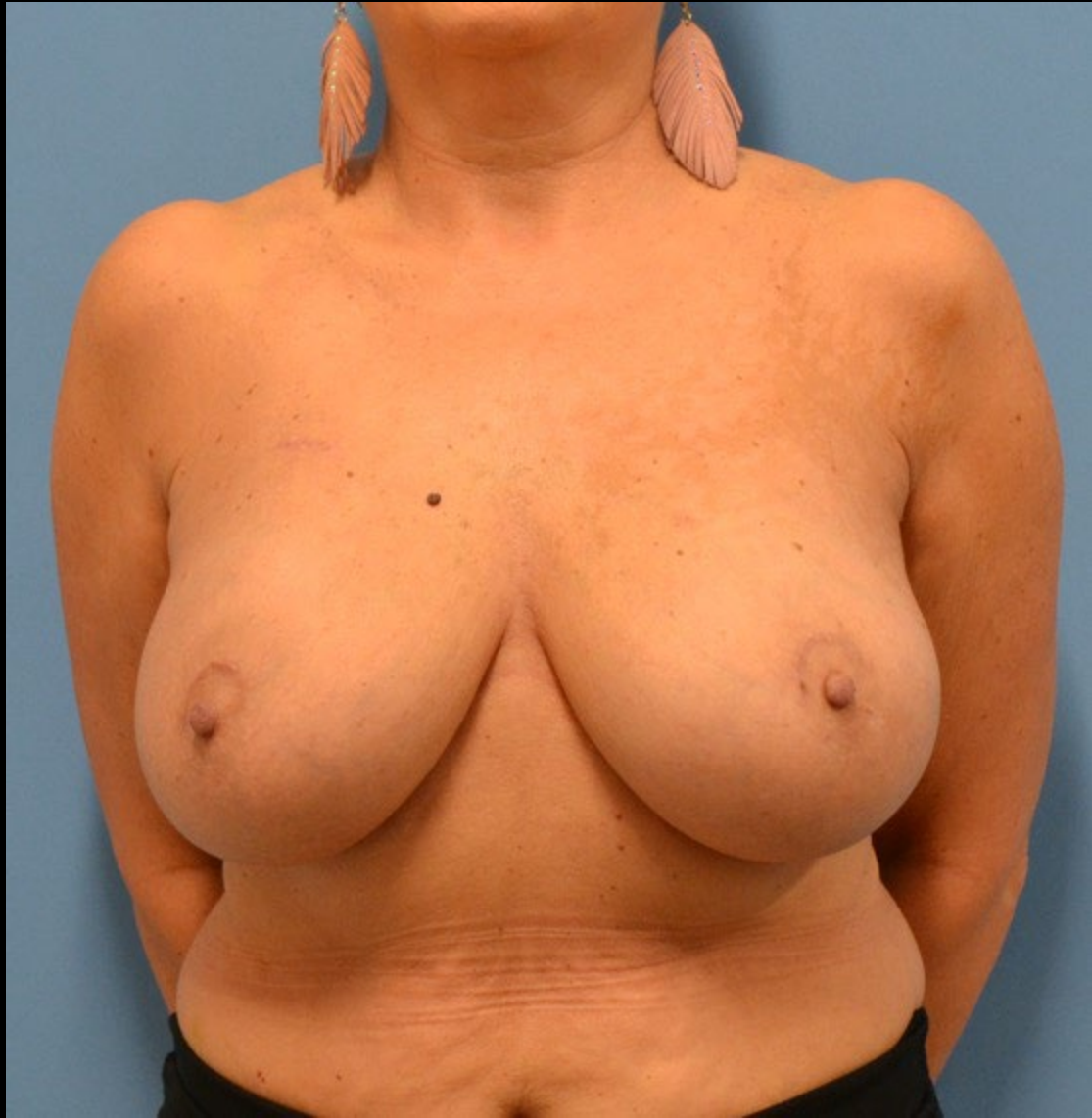
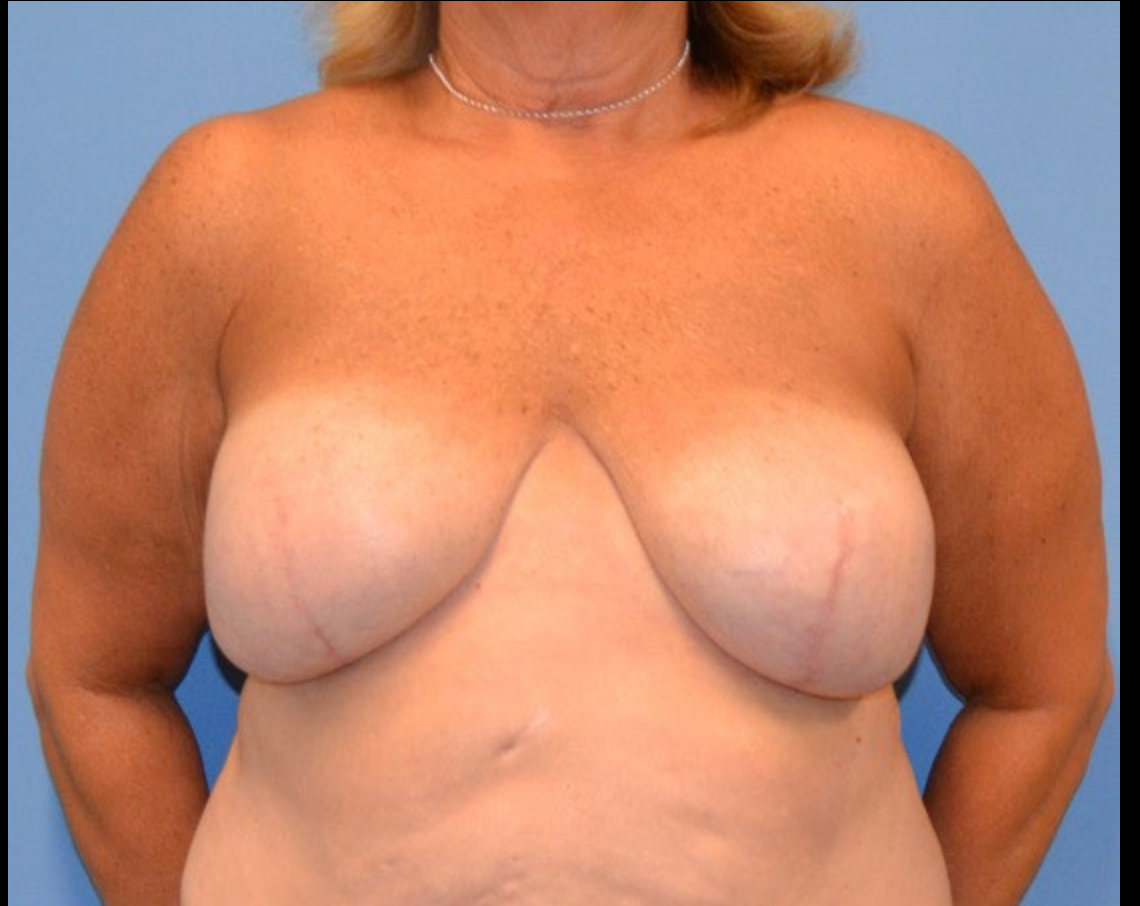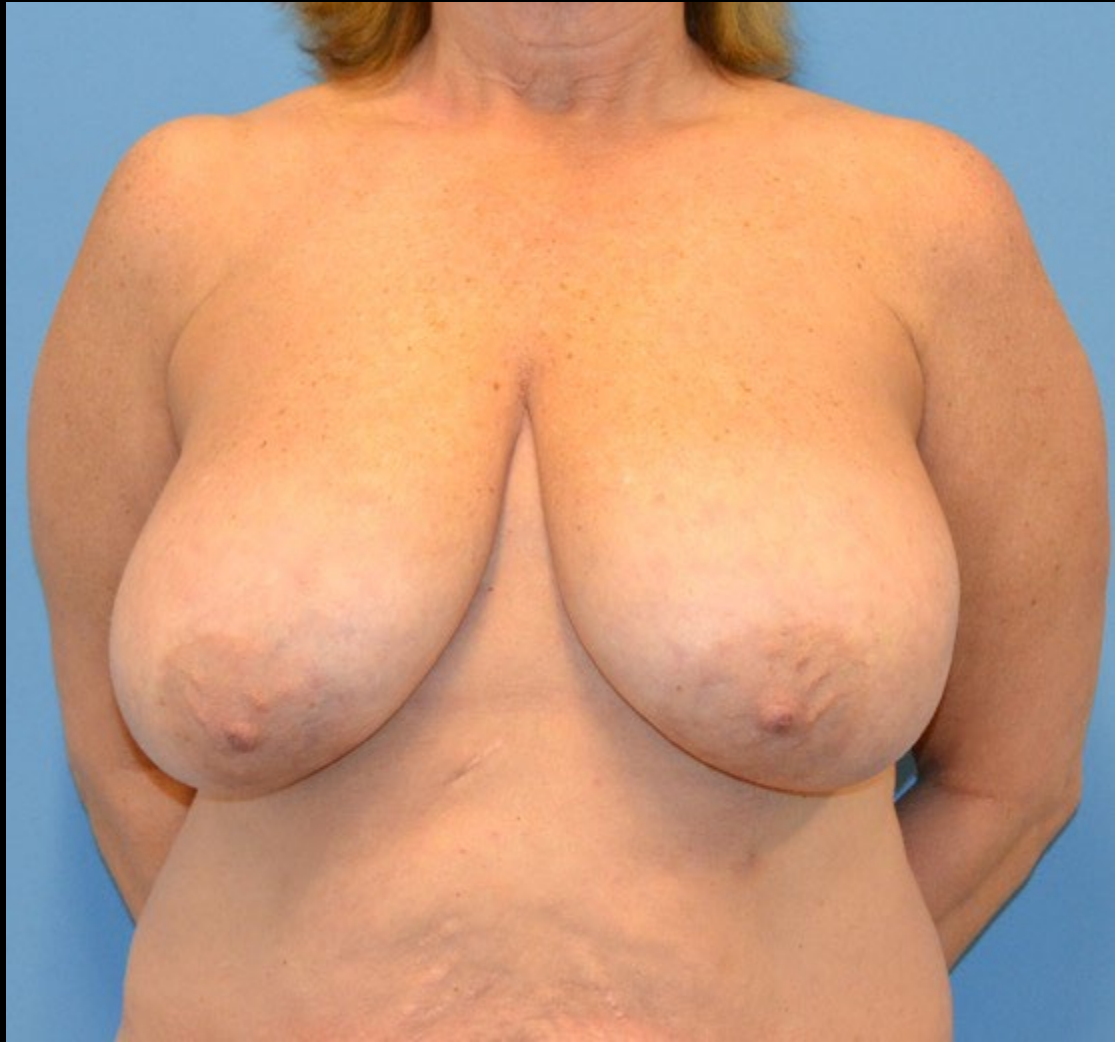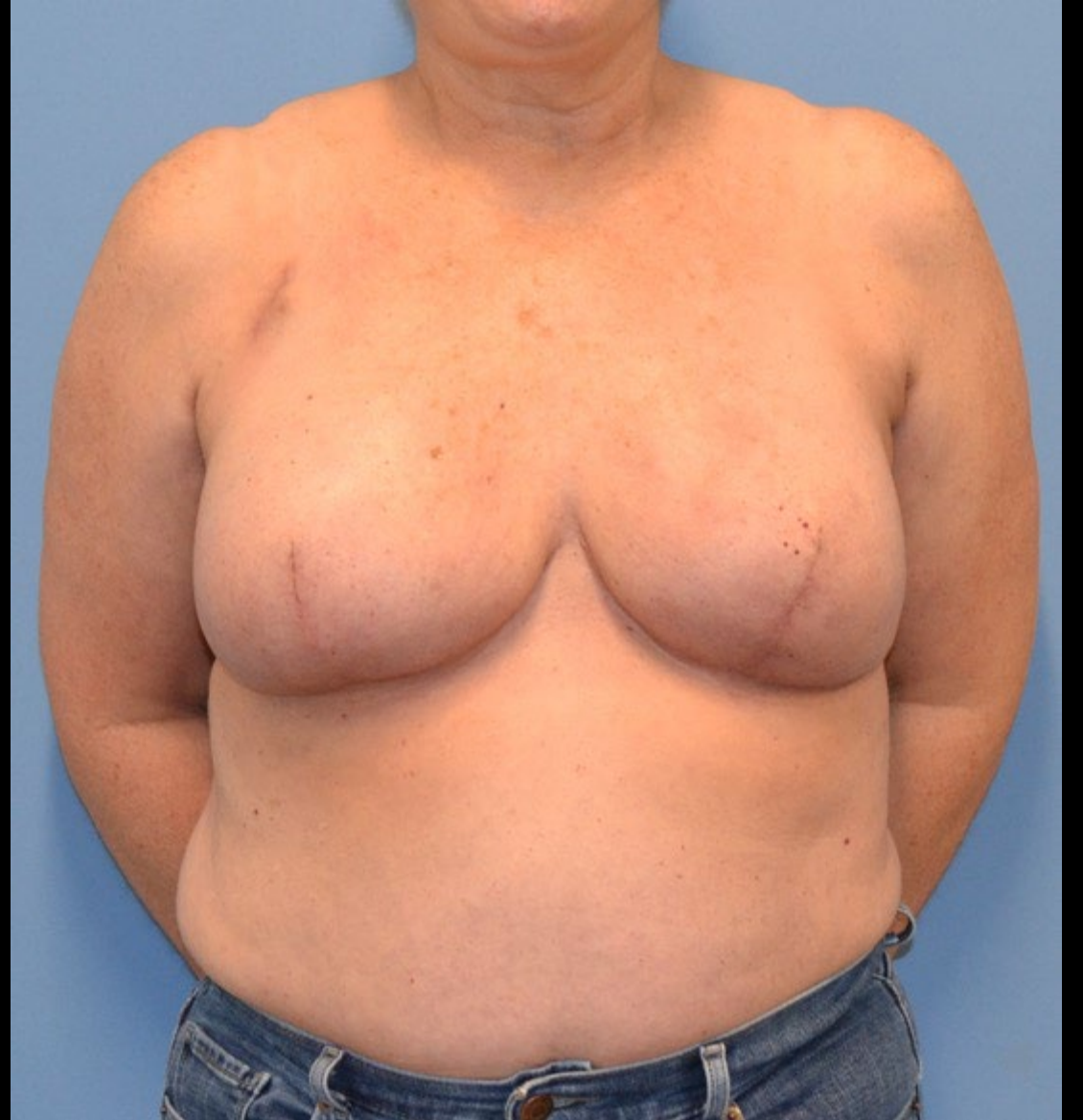






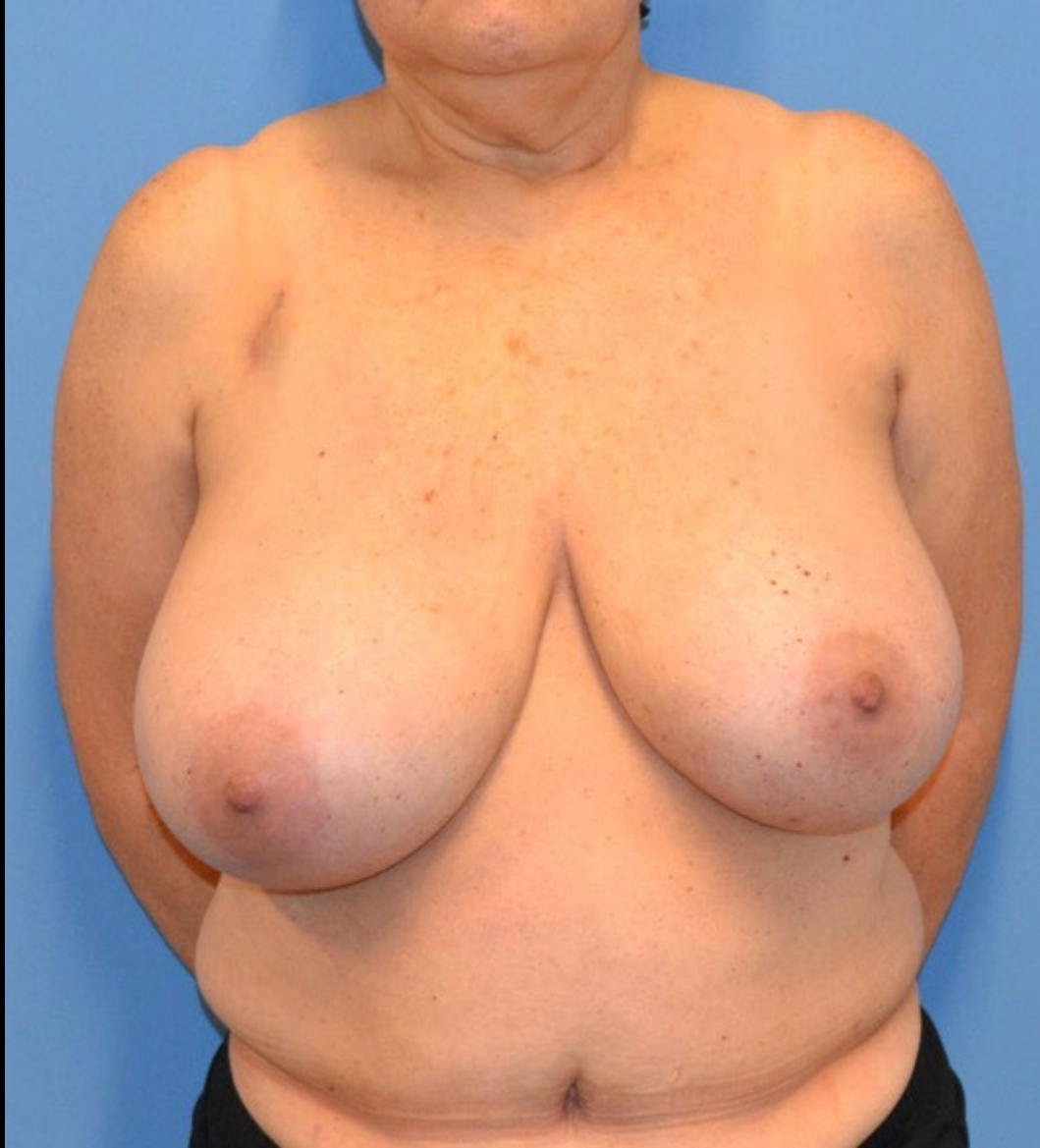





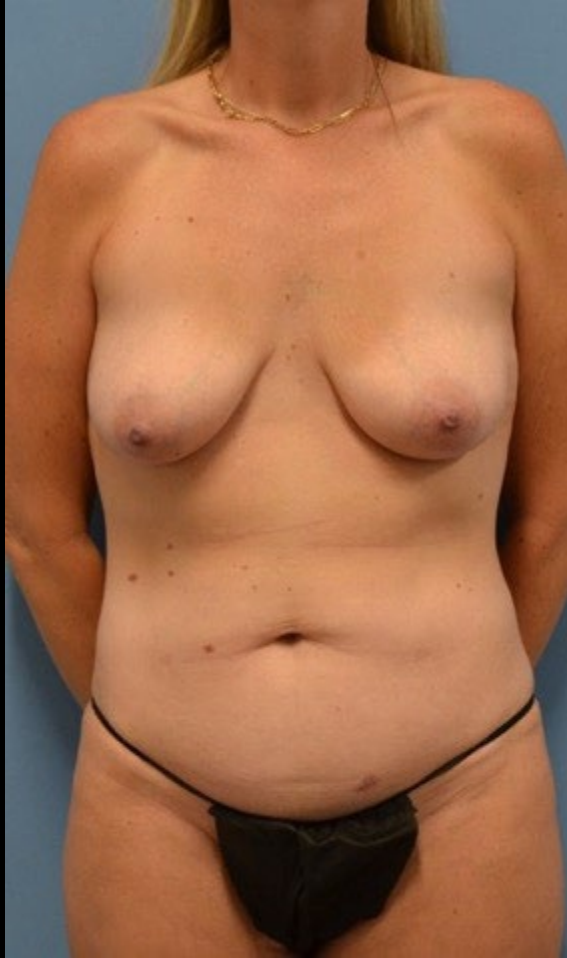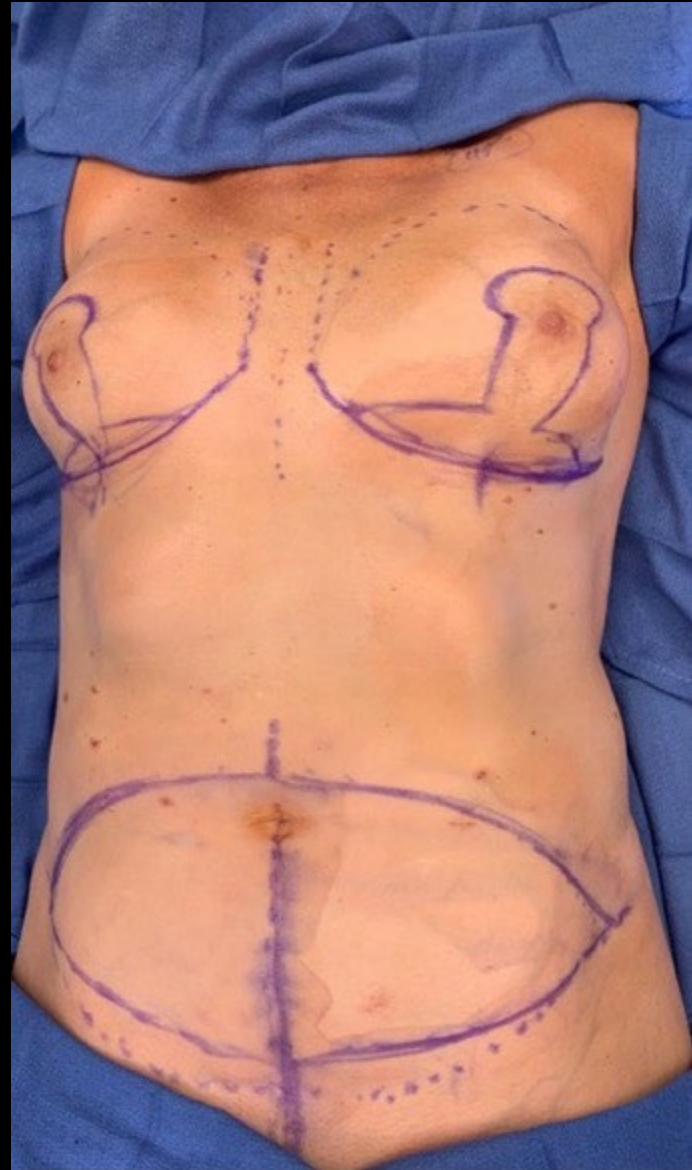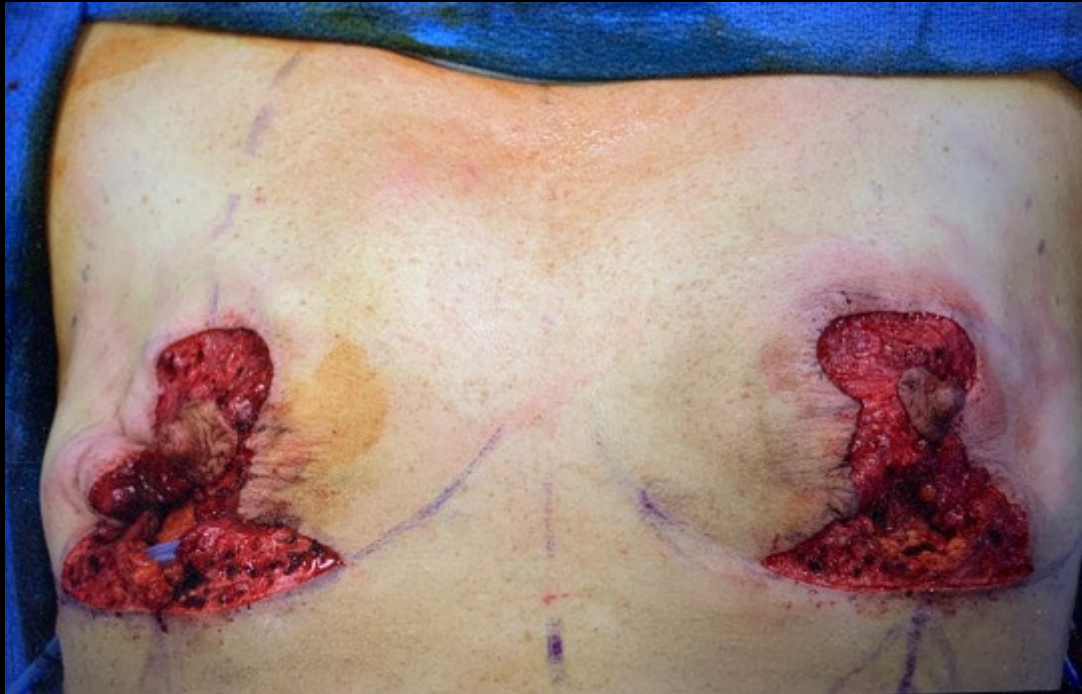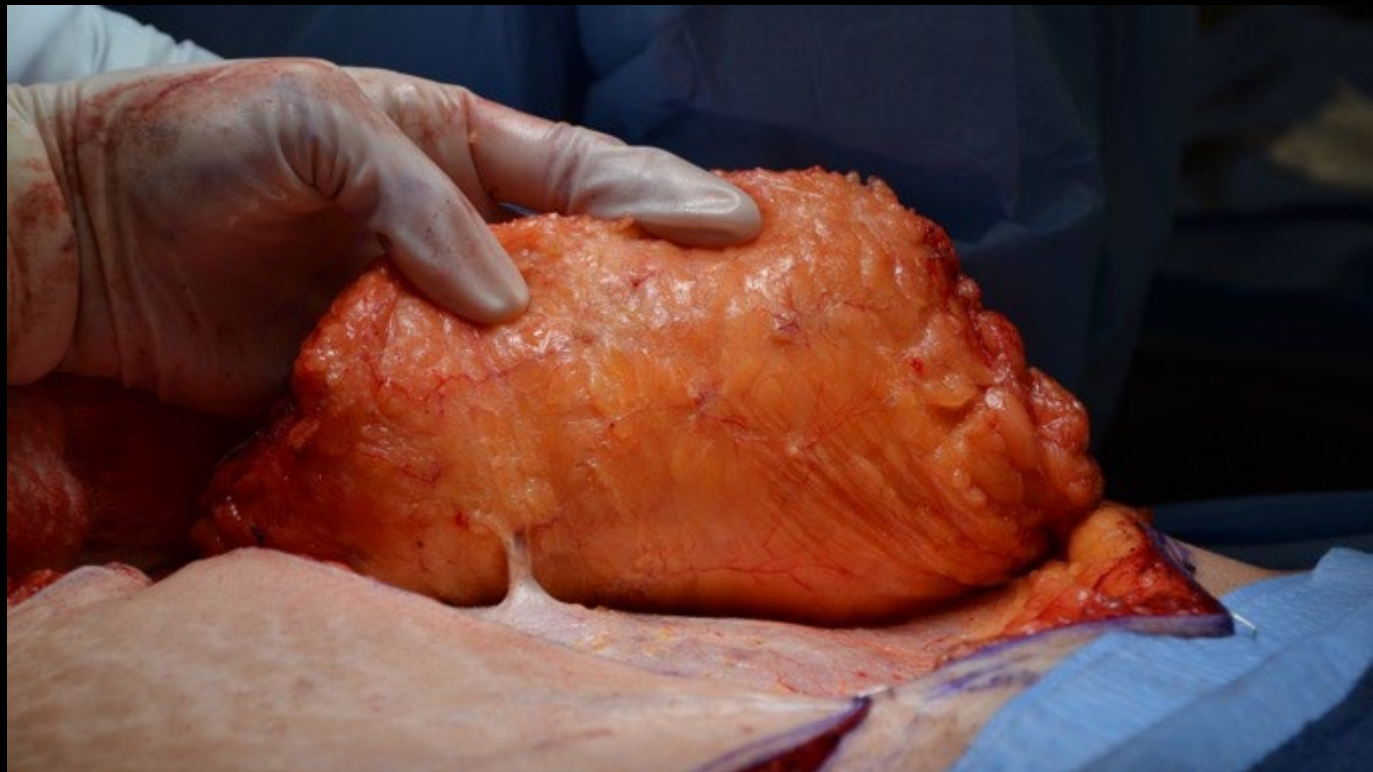
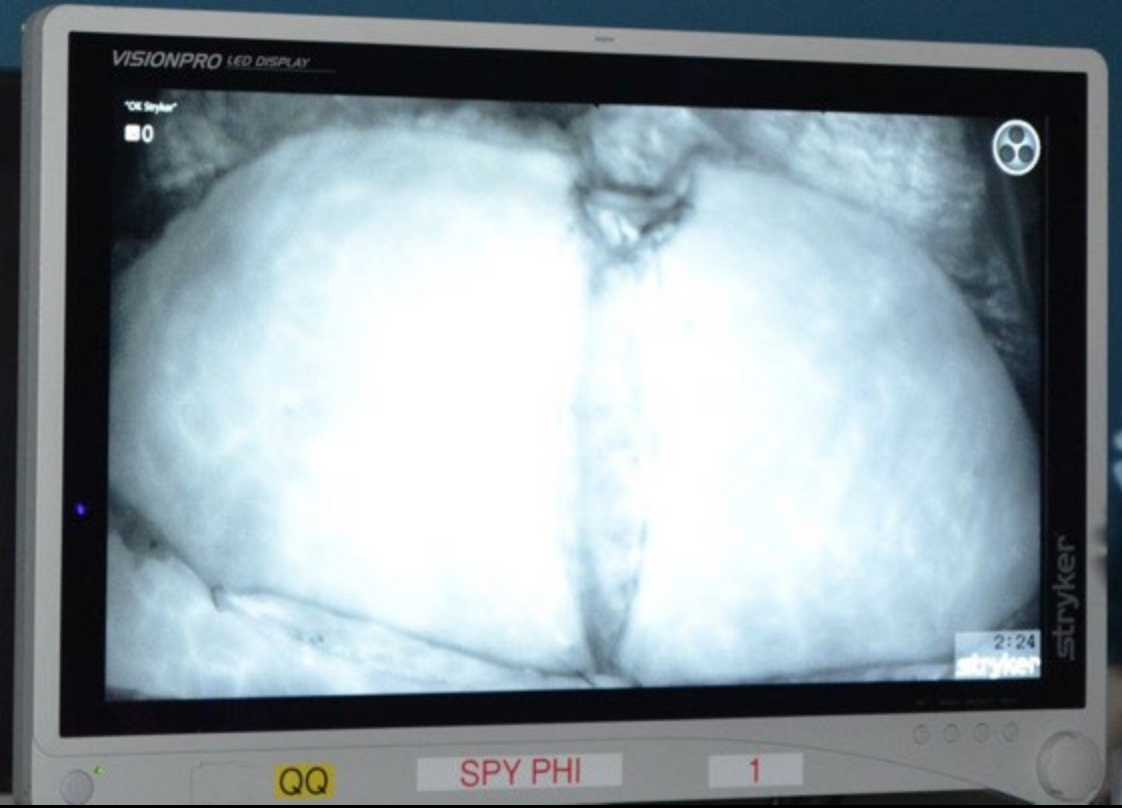# Skin-Only Mastopexy: Immediate or Delayed

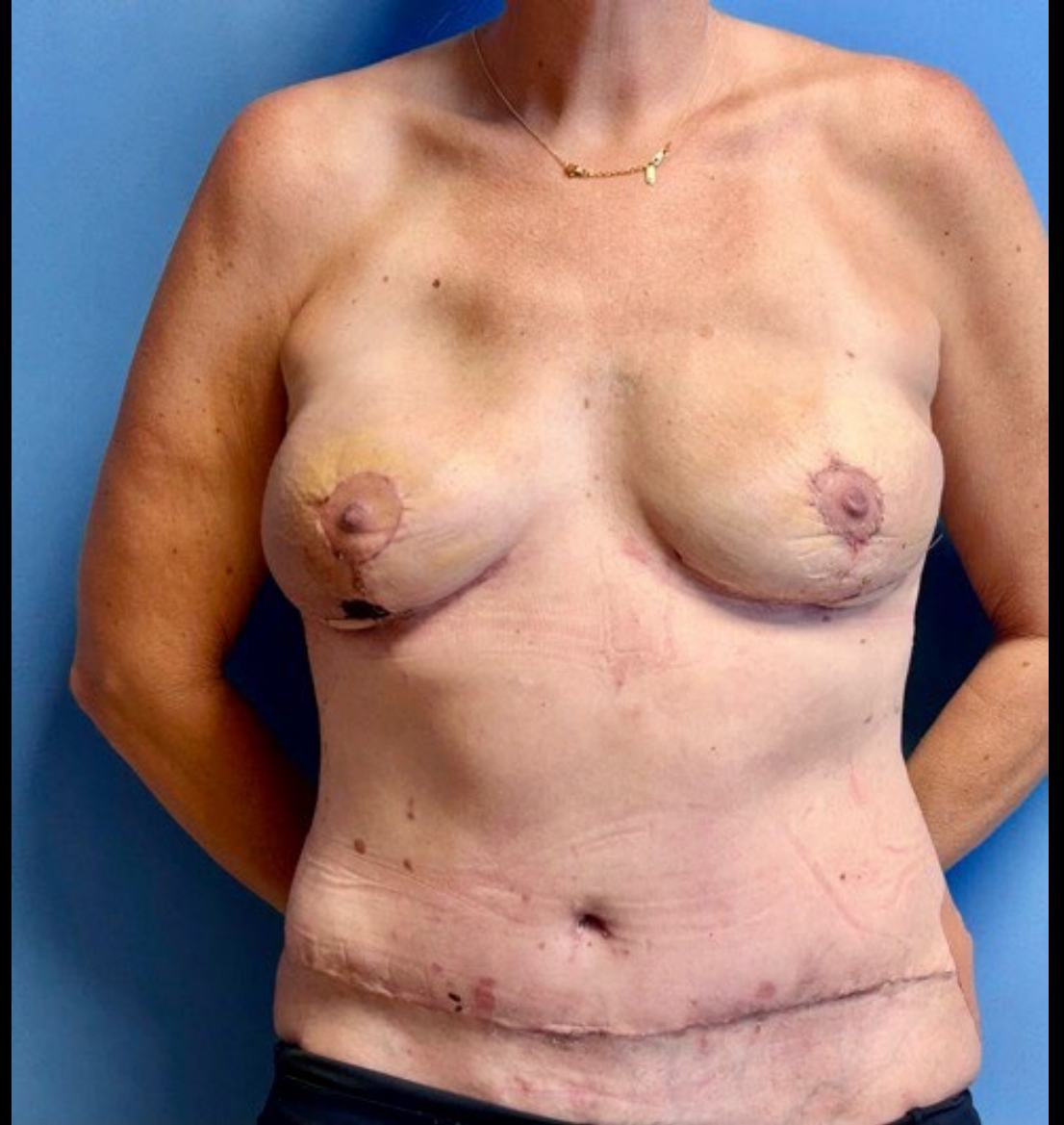
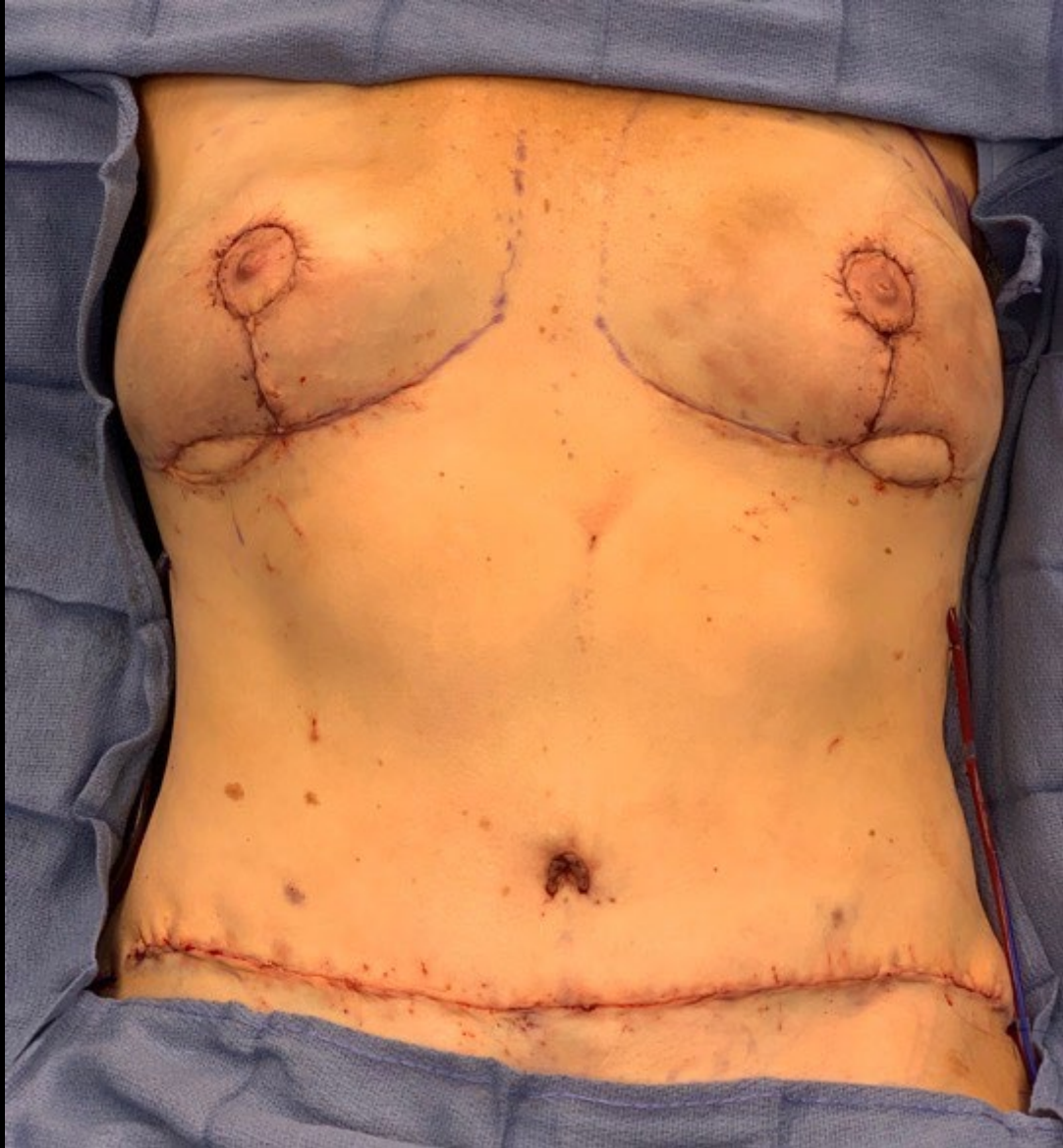


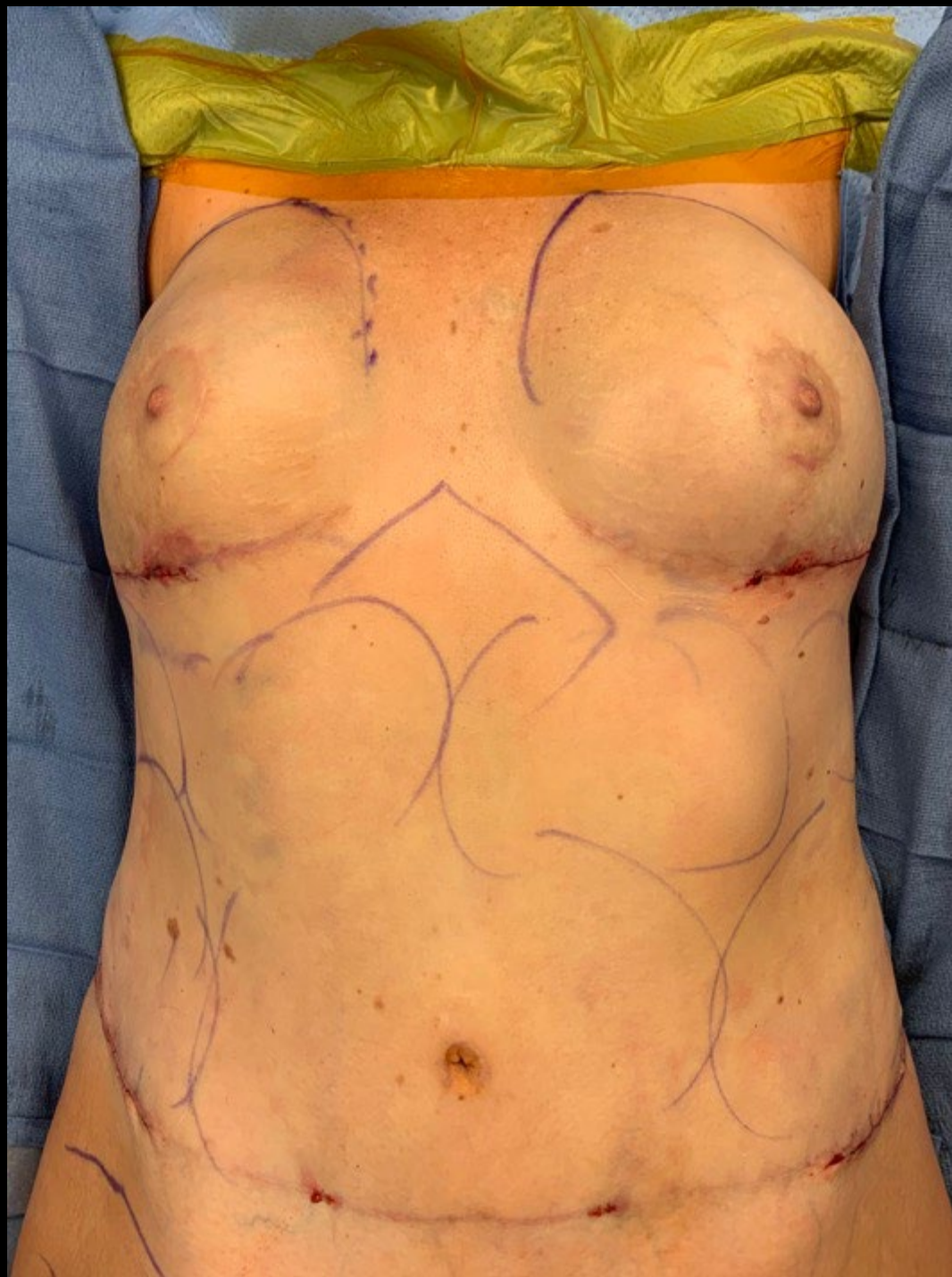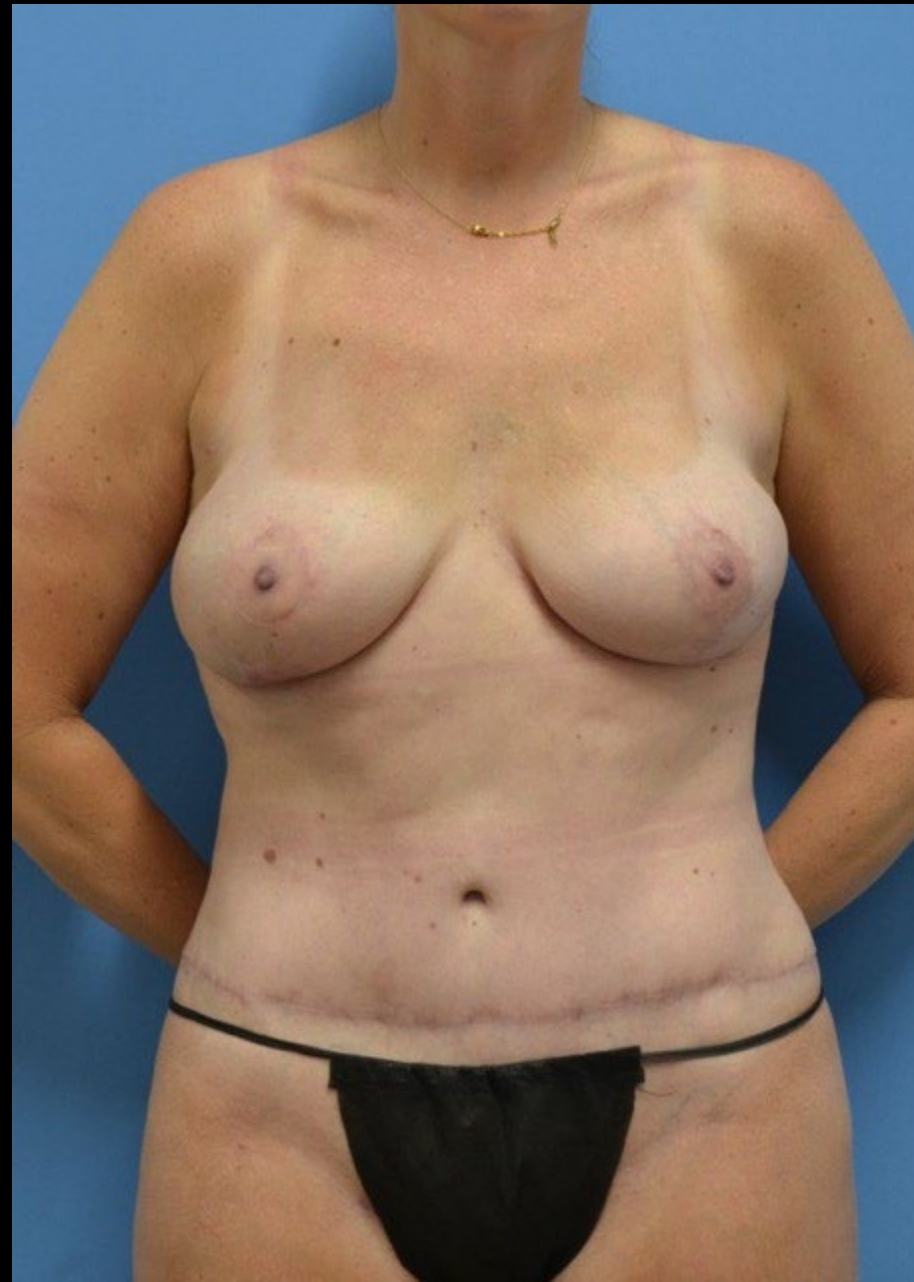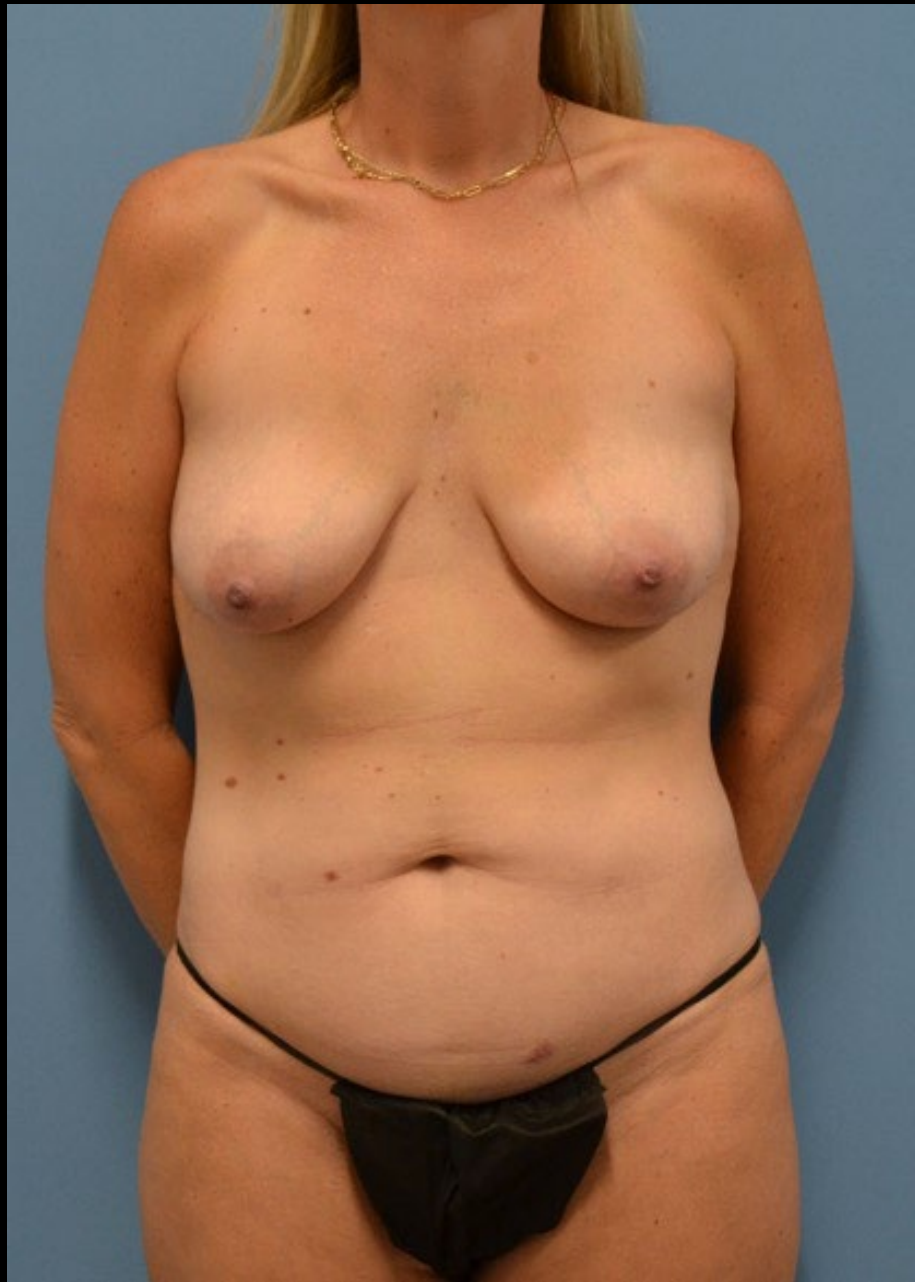- BRCA1 positive
- Nipple sparing mastectomy, immediate DIEP, skin-only mastopexy

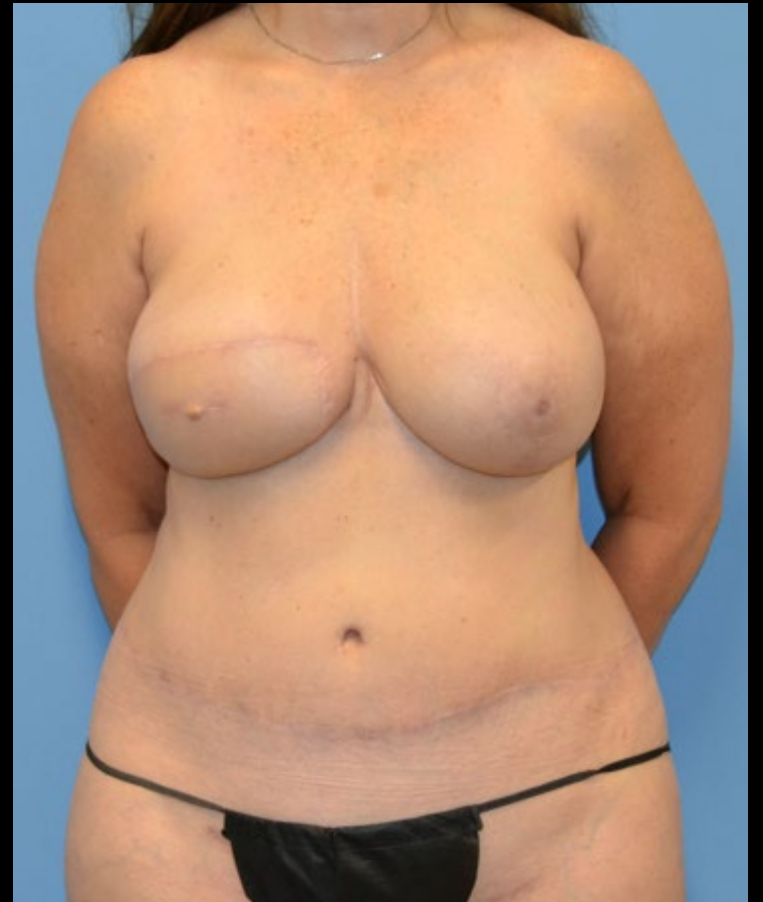
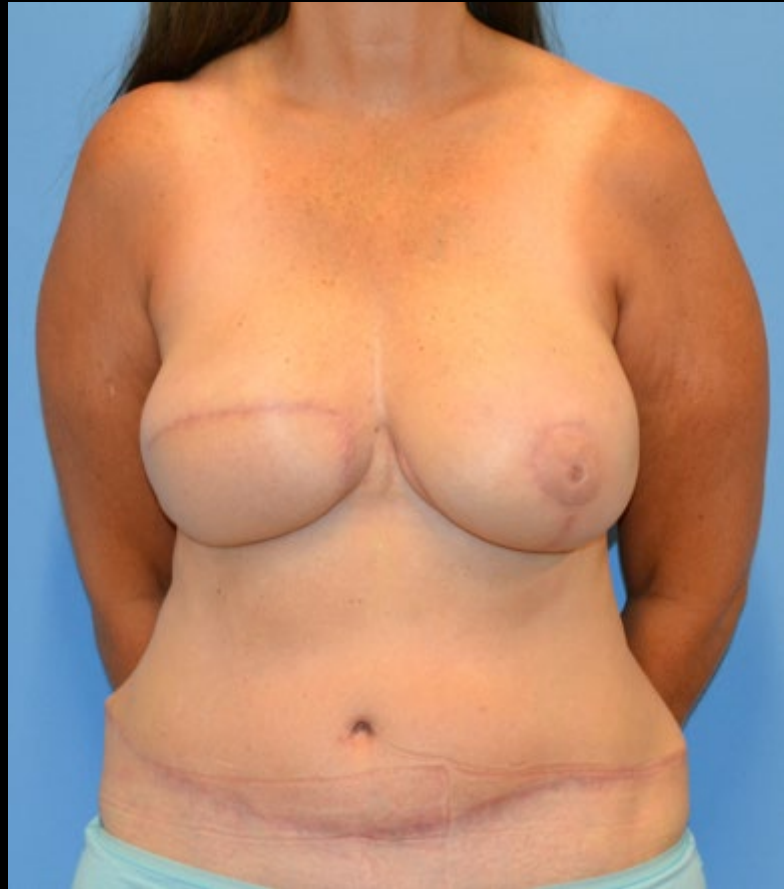
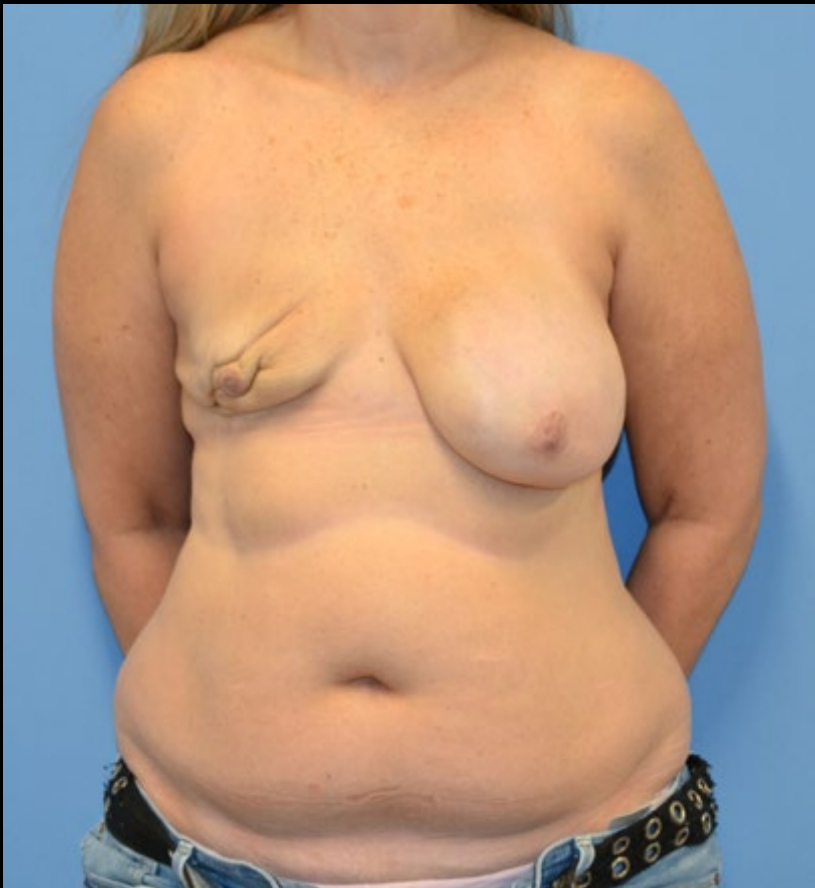




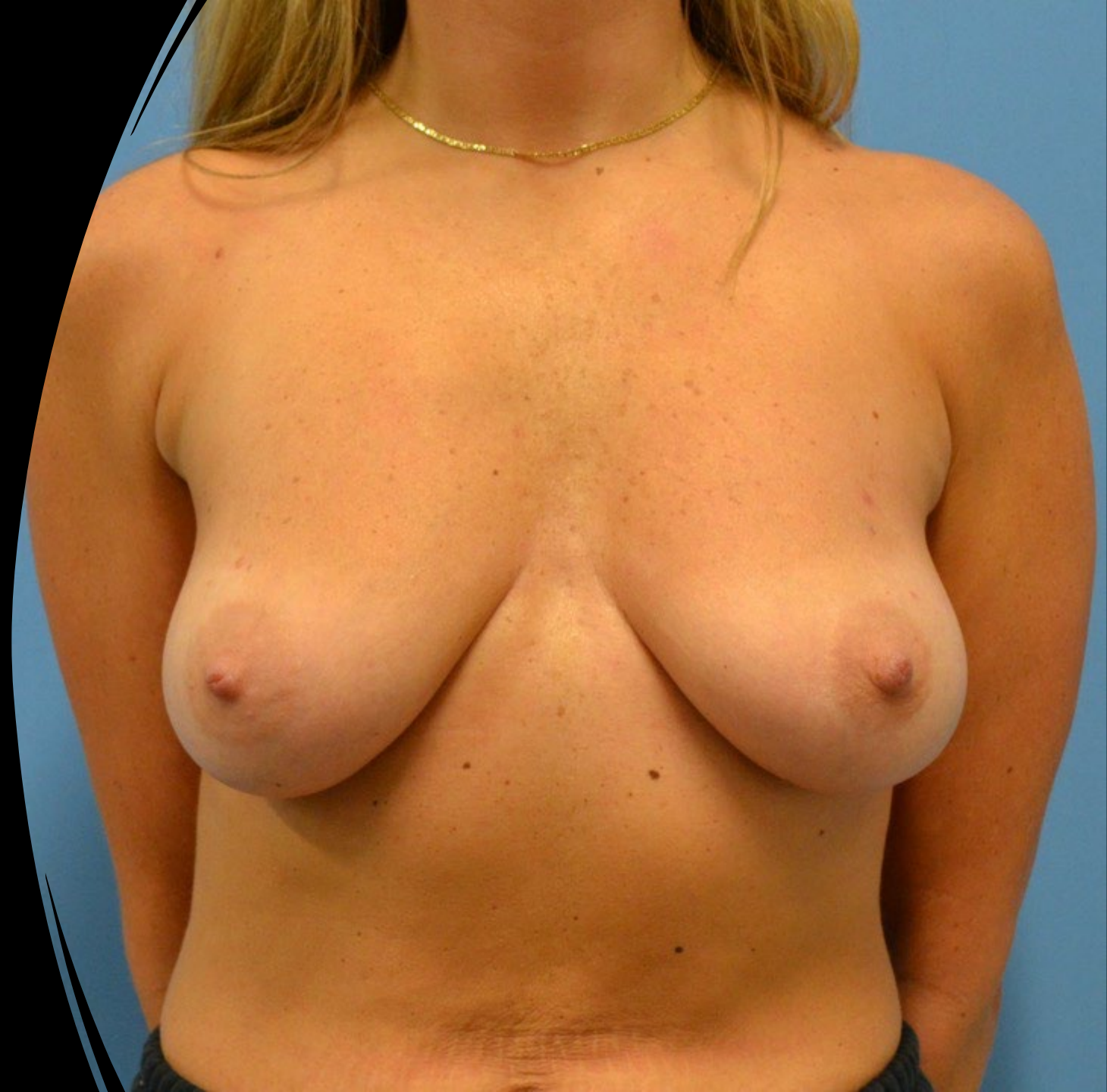
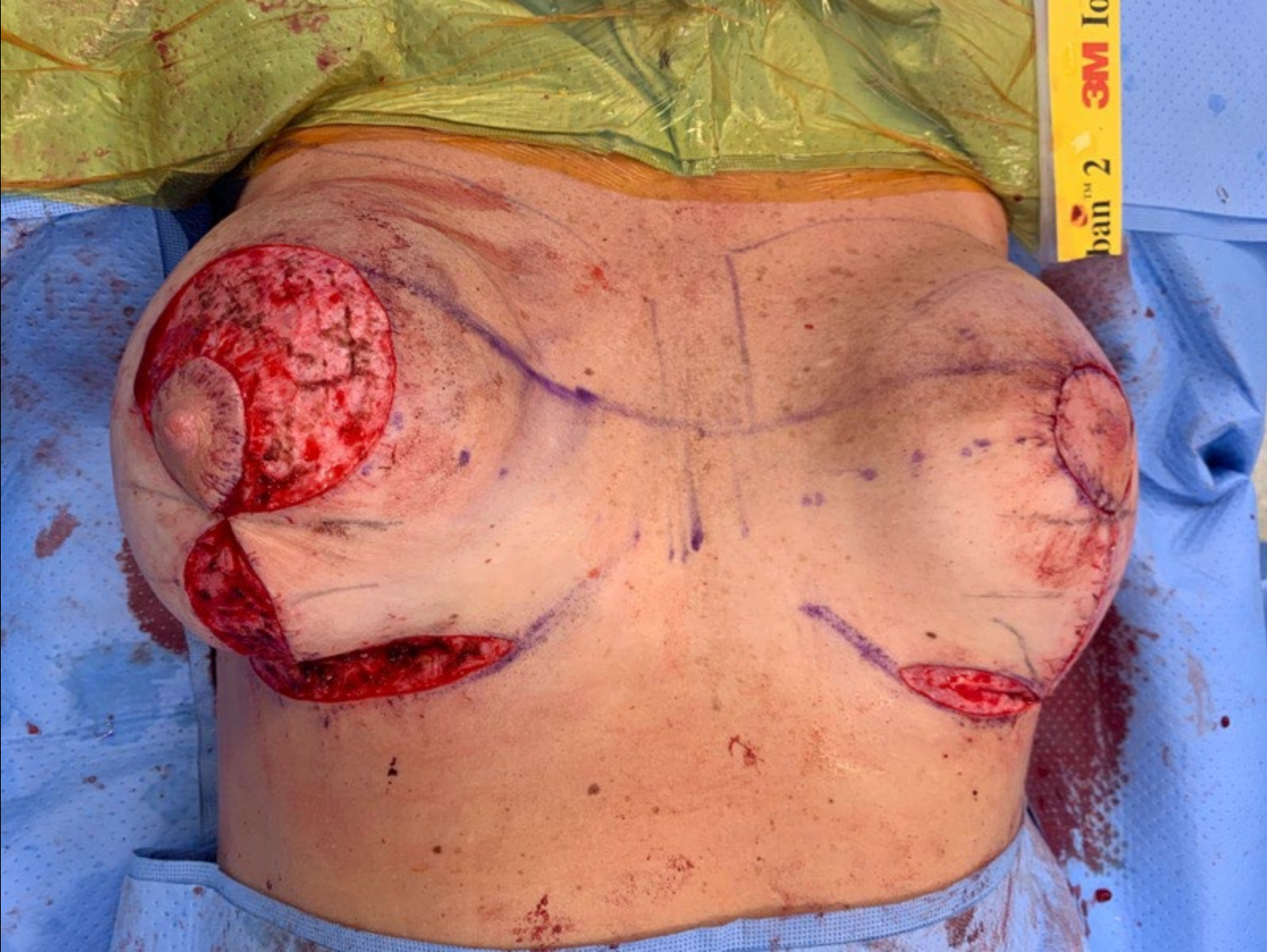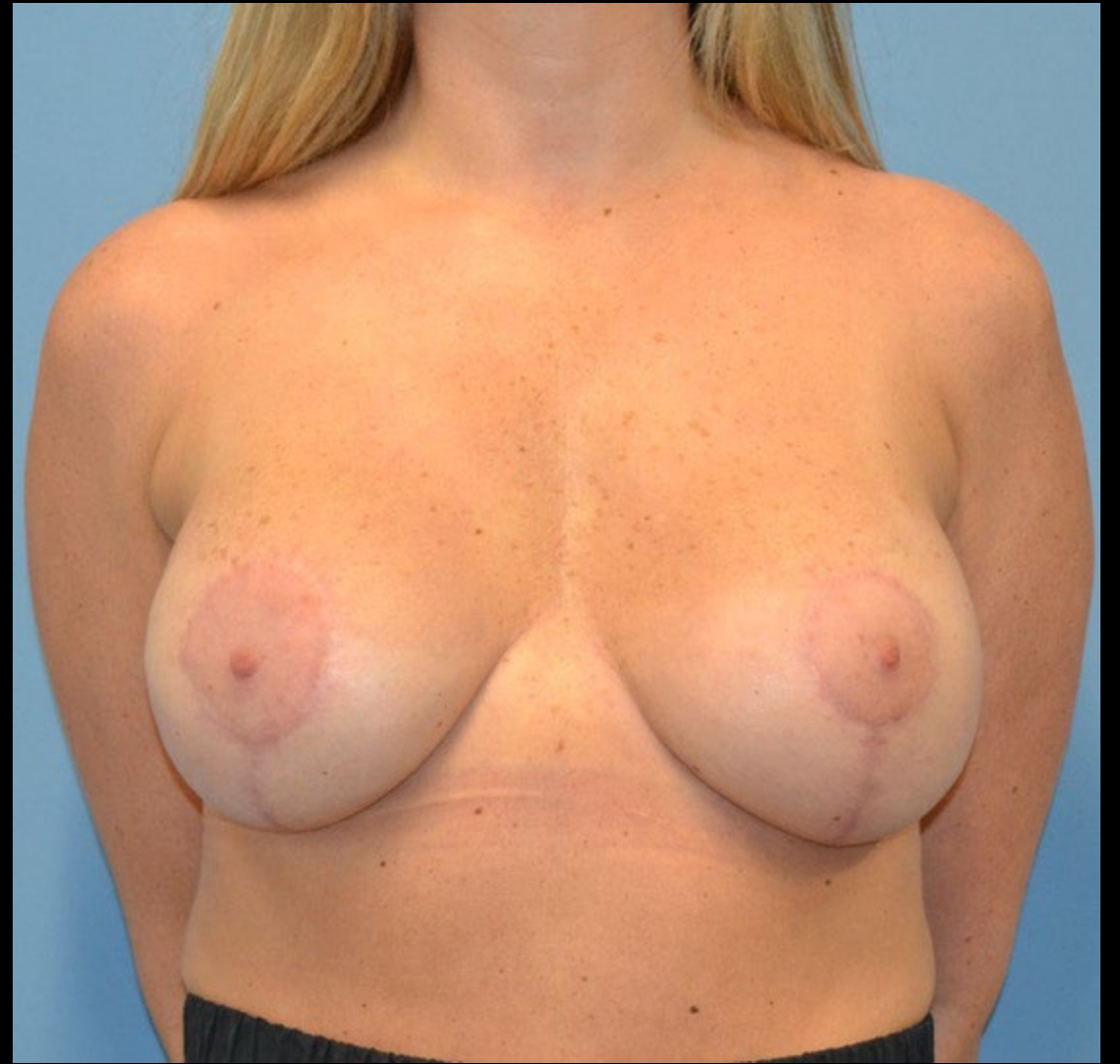




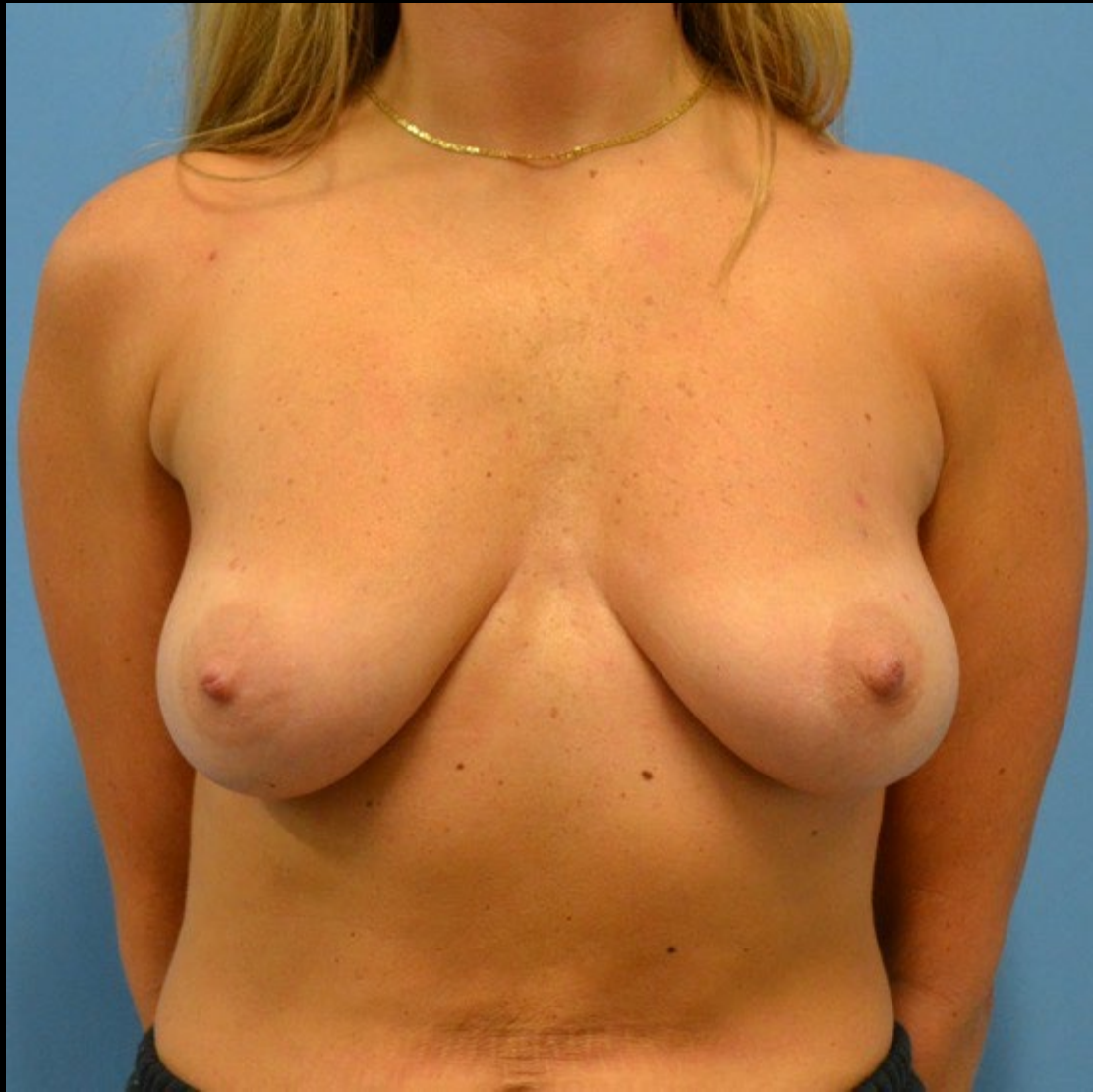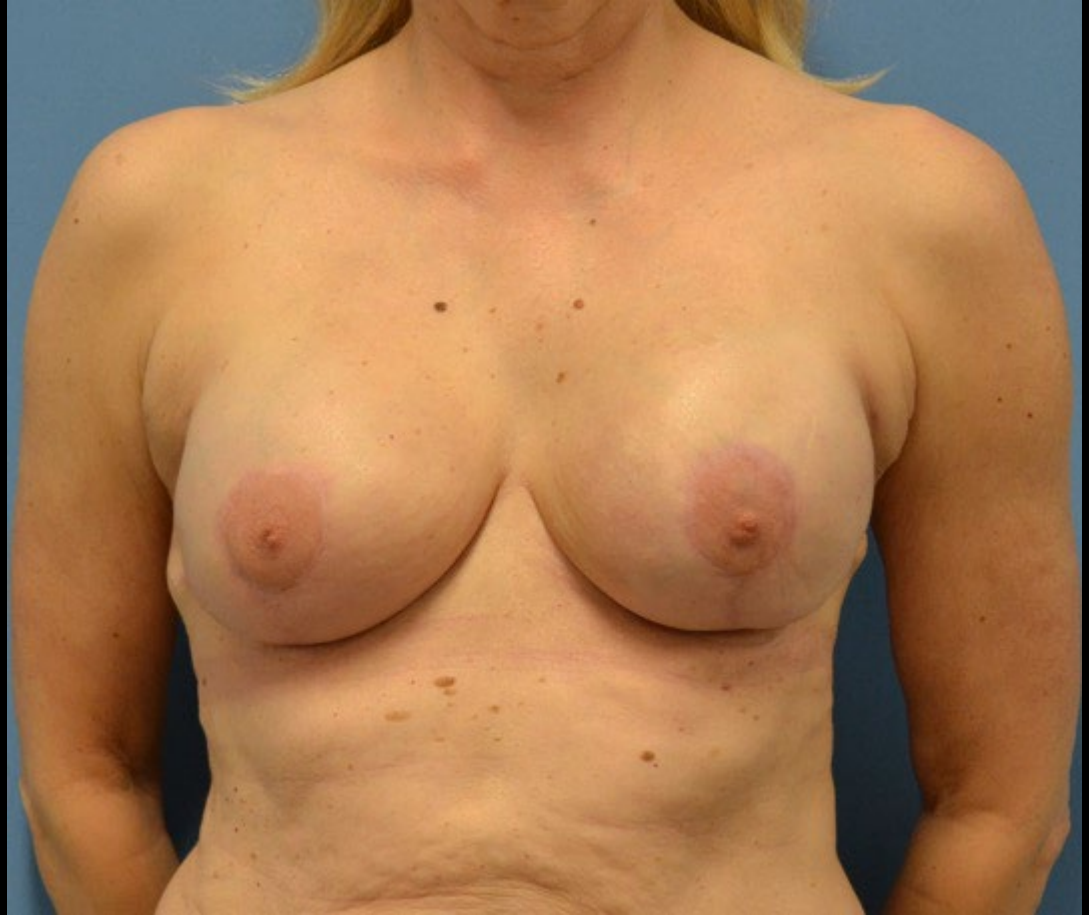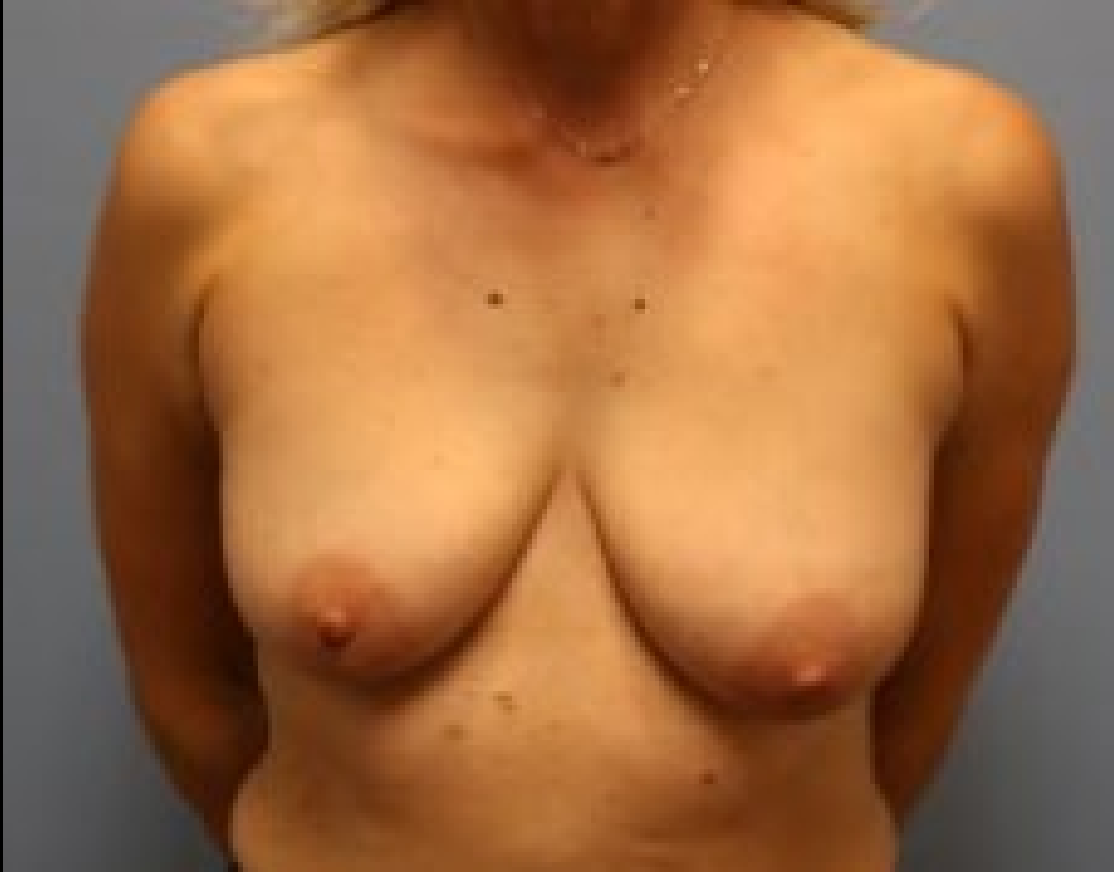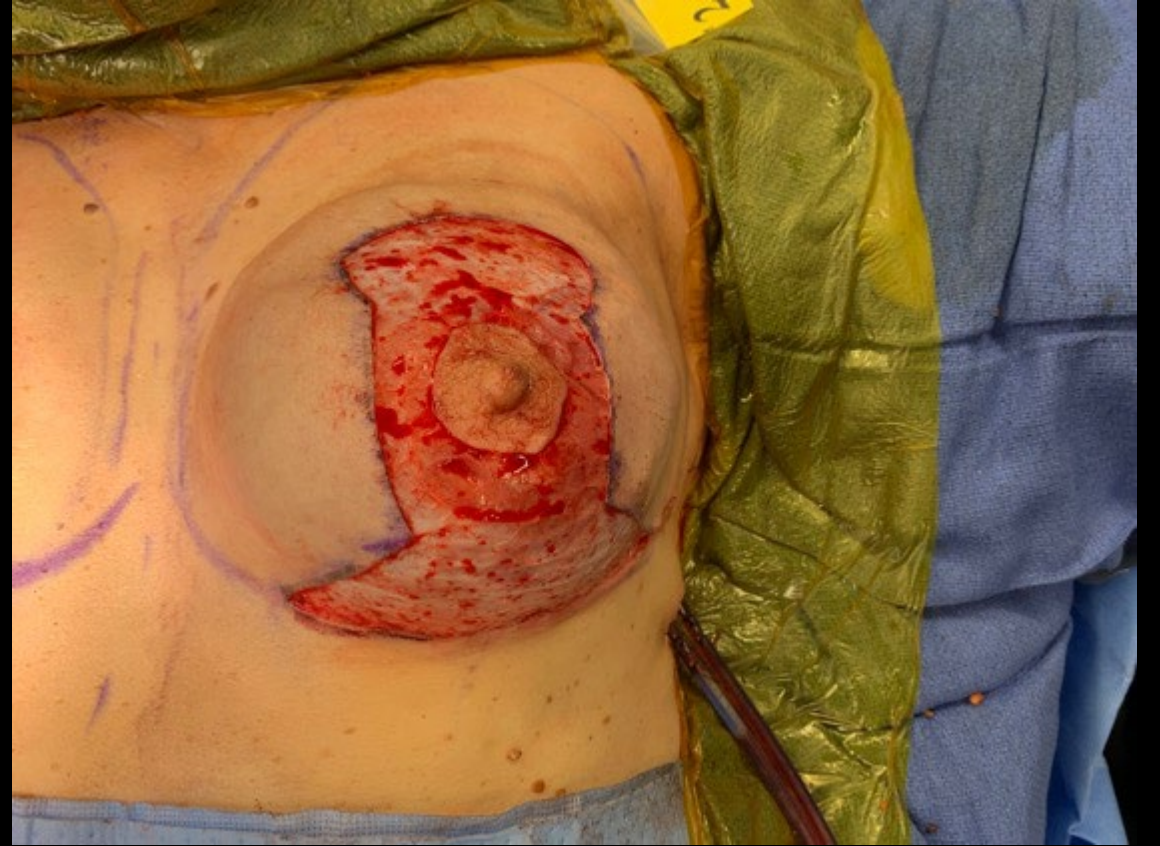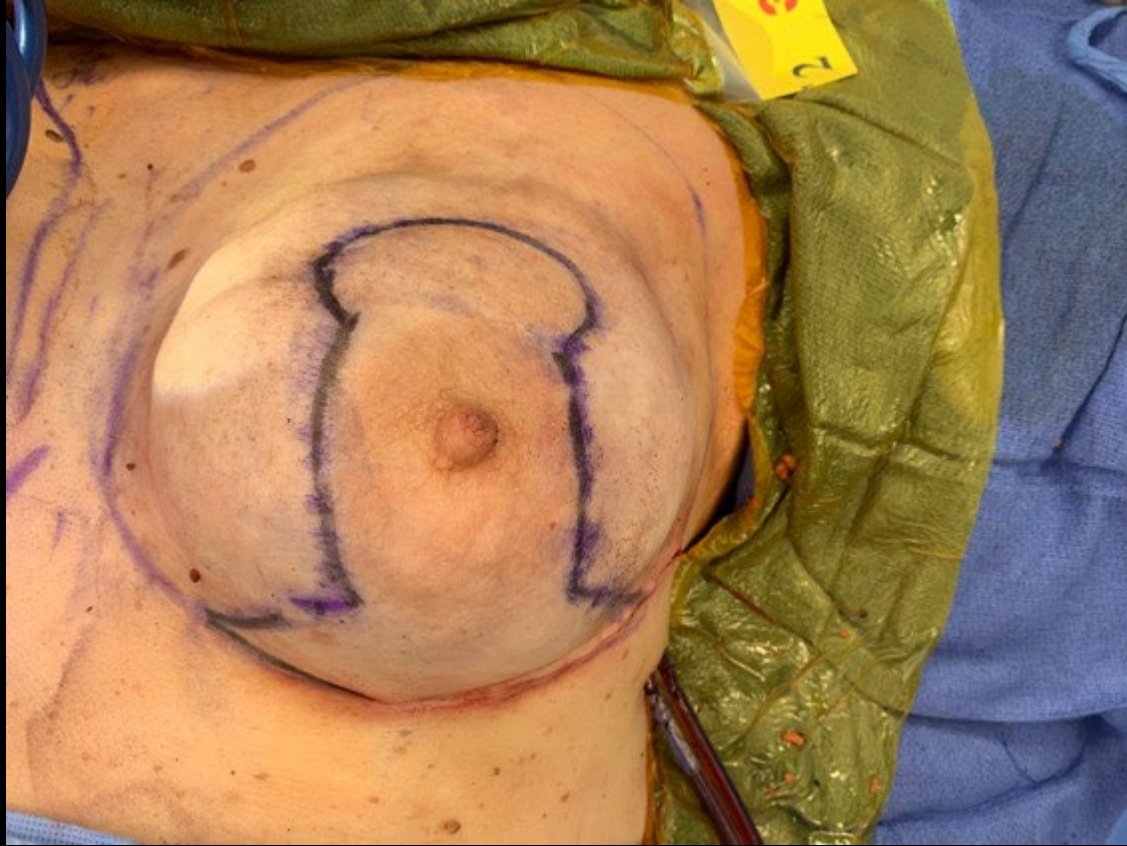- 
- Hormone positive L breast cancer
  - Nipple sparing mastectomy
  - Implant reconstruction
  - Delayed skin-only mastopexy

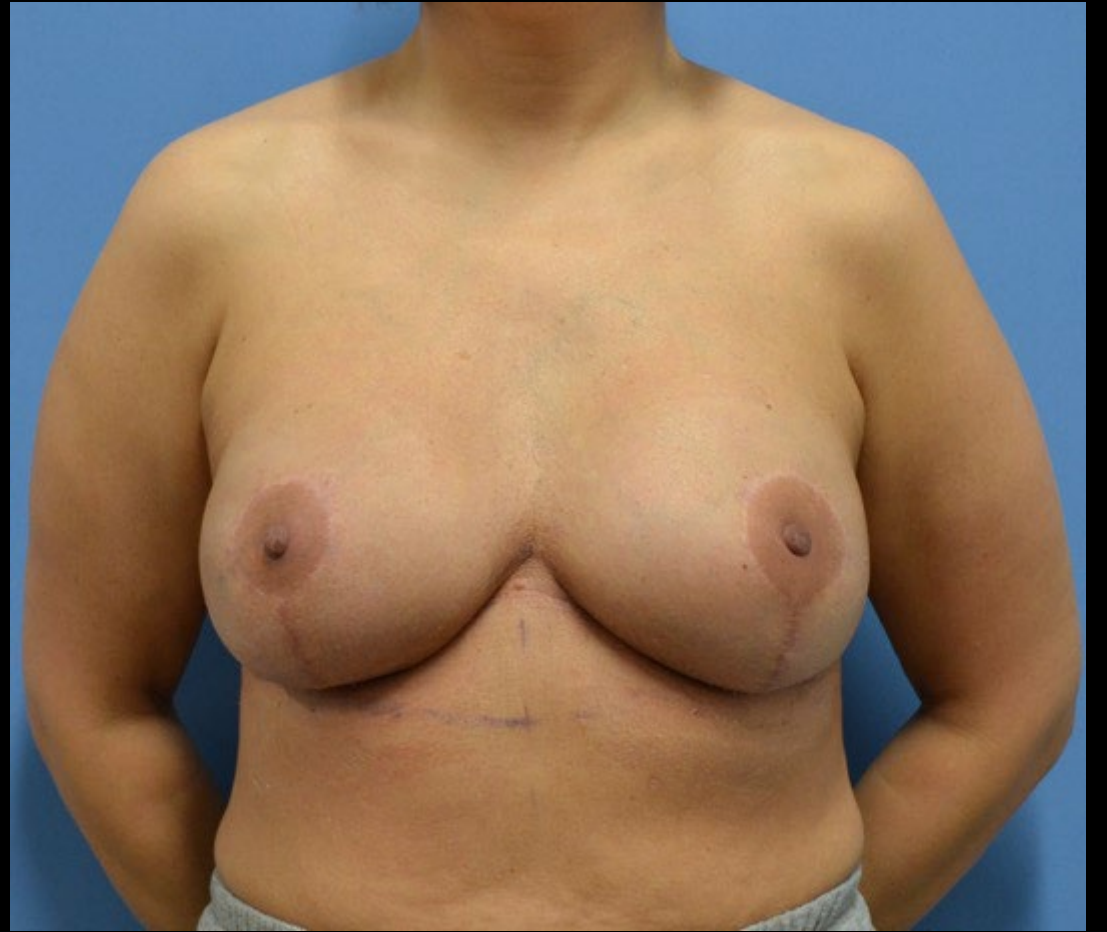
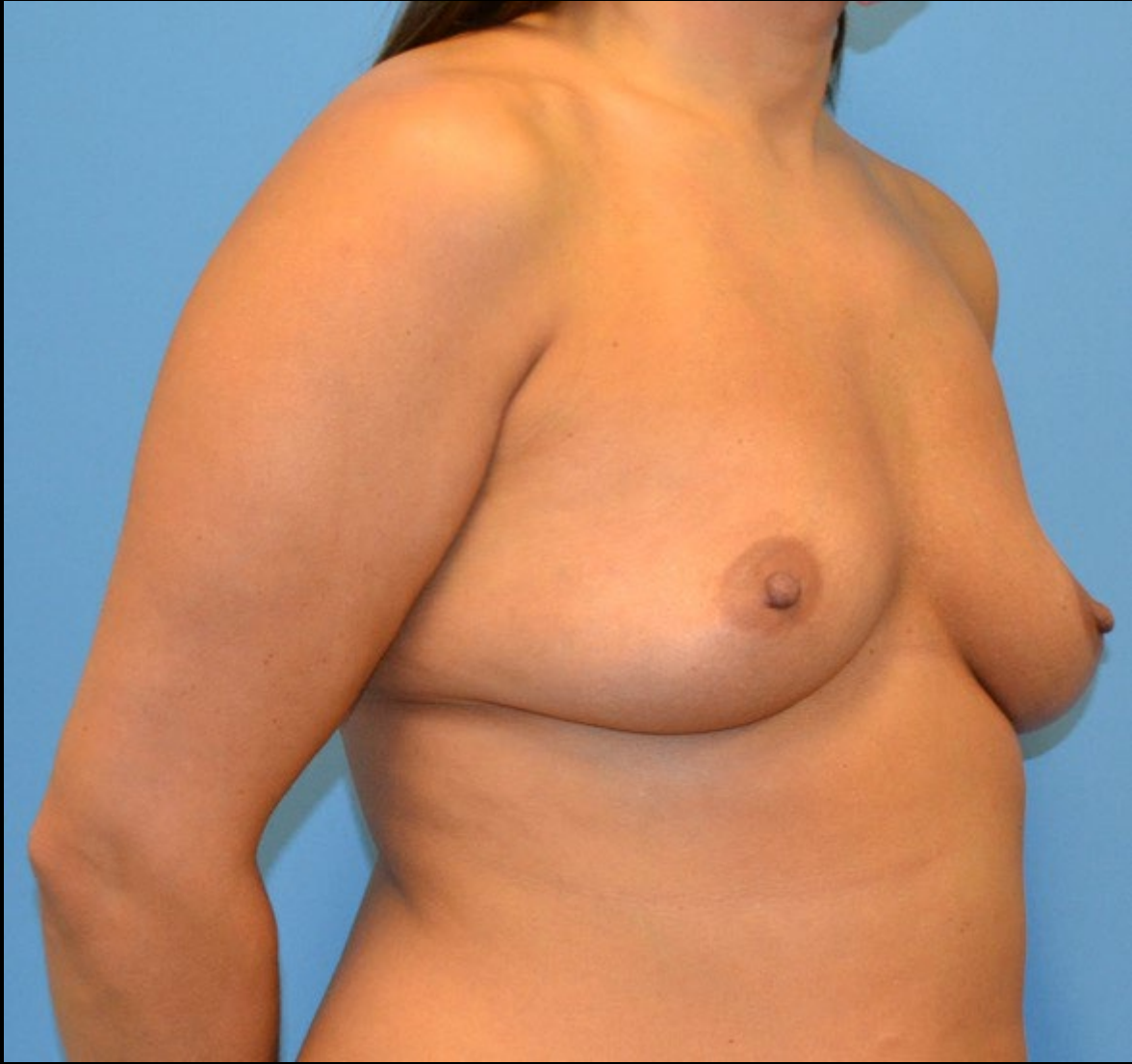

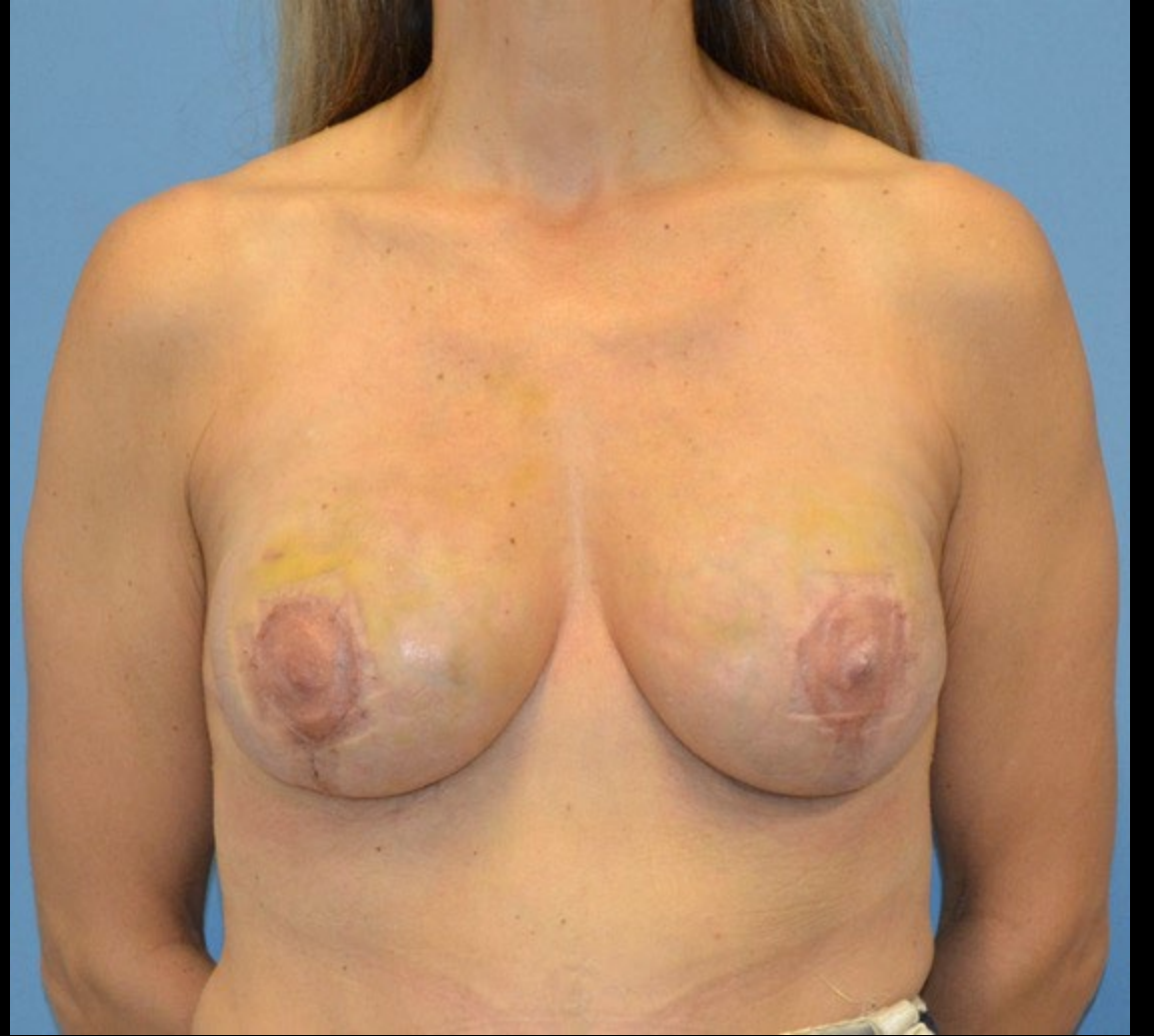

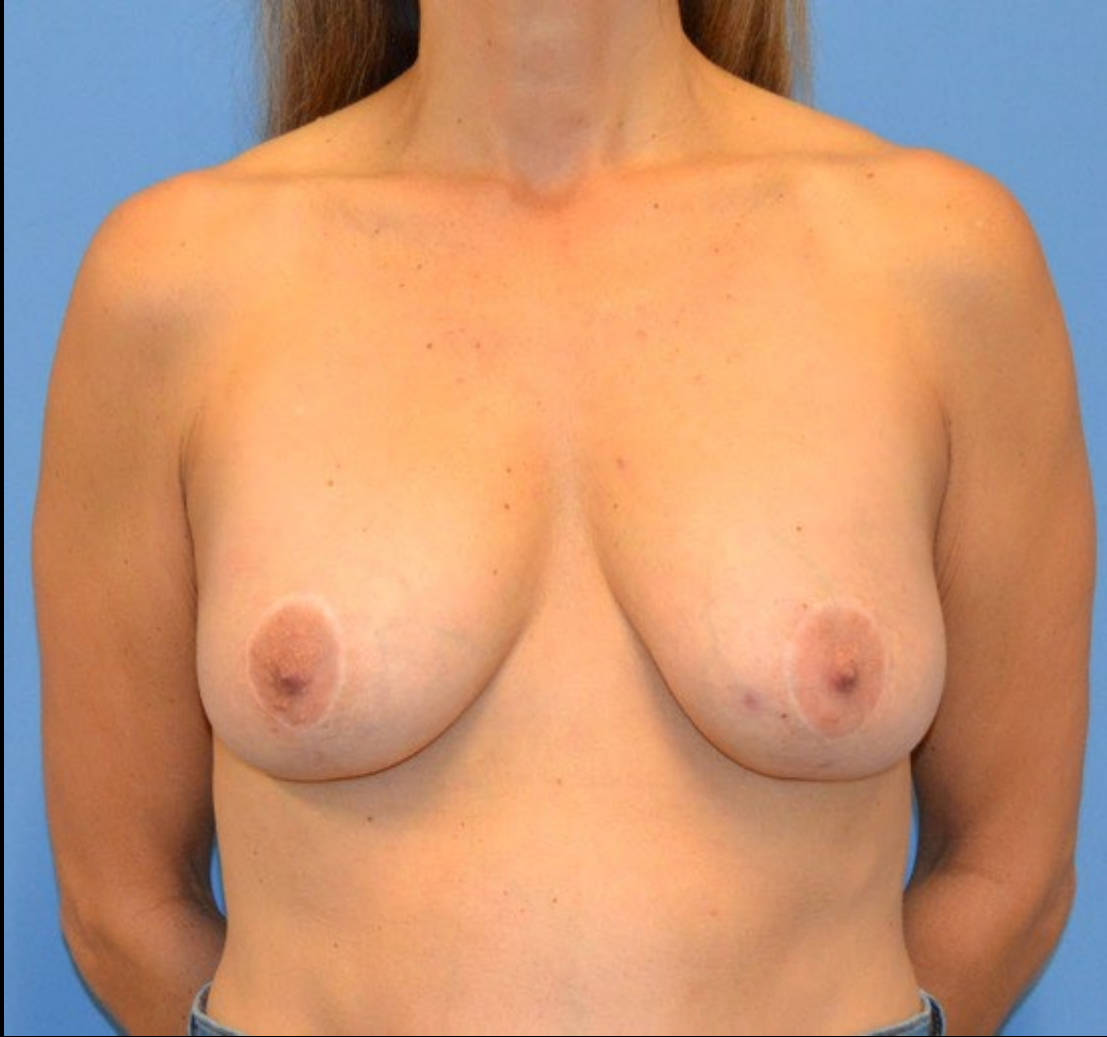


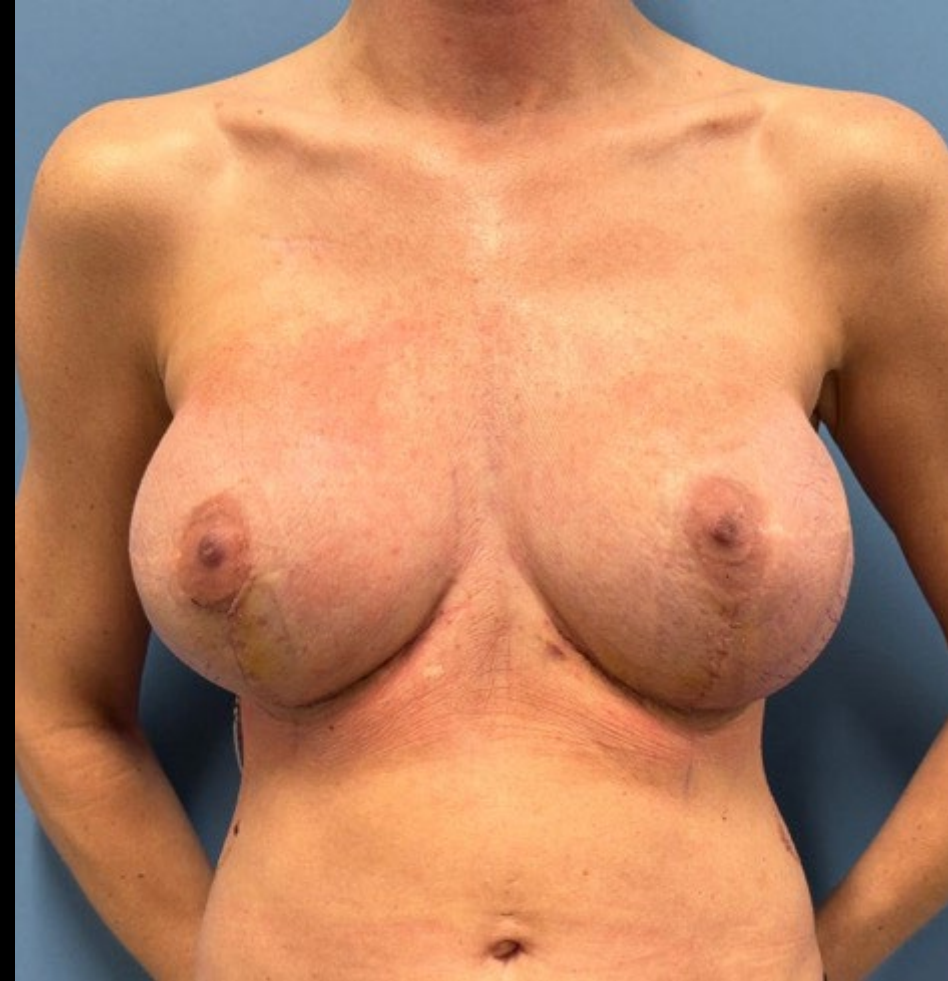
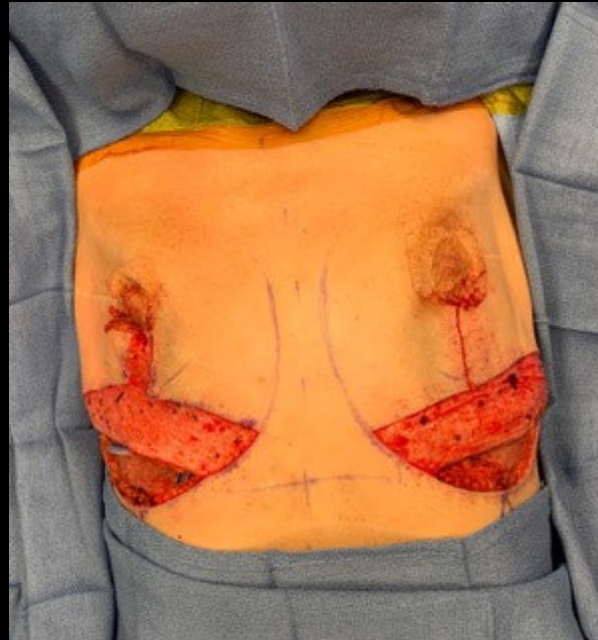
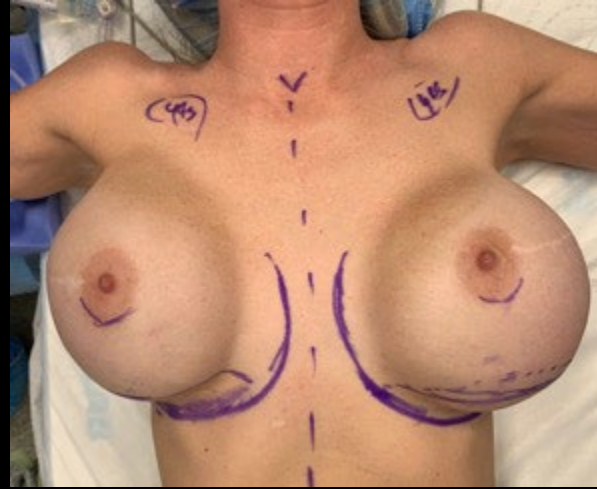
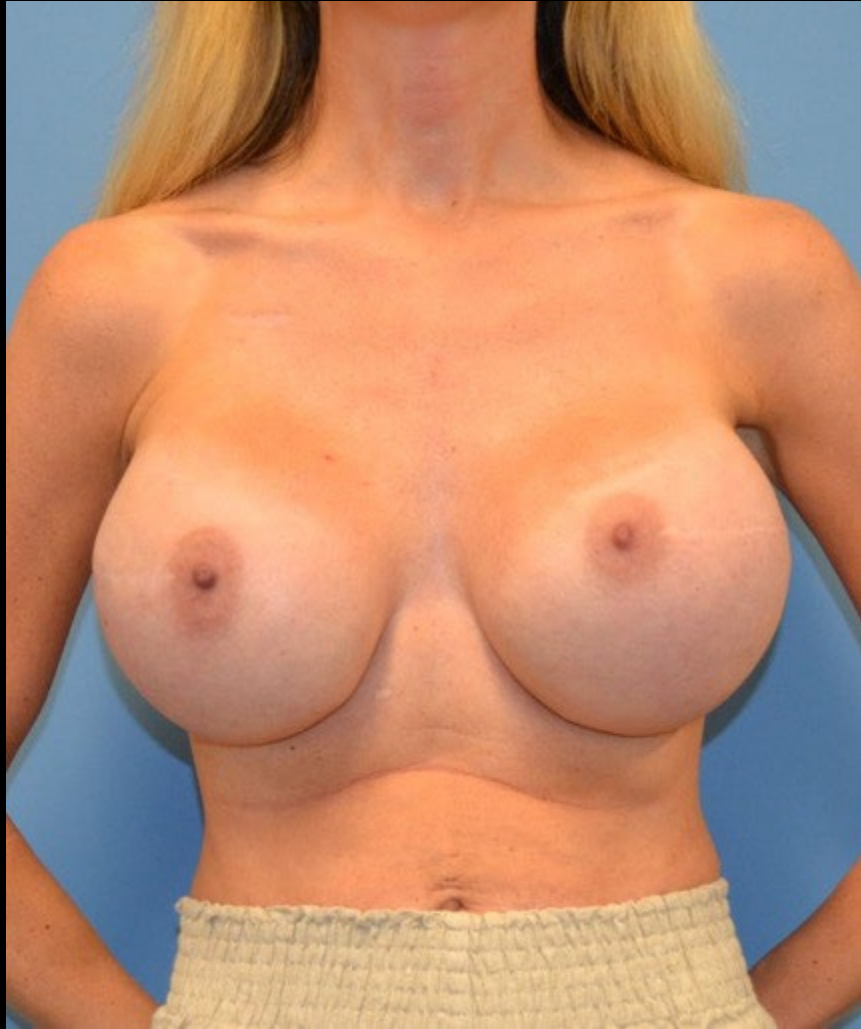






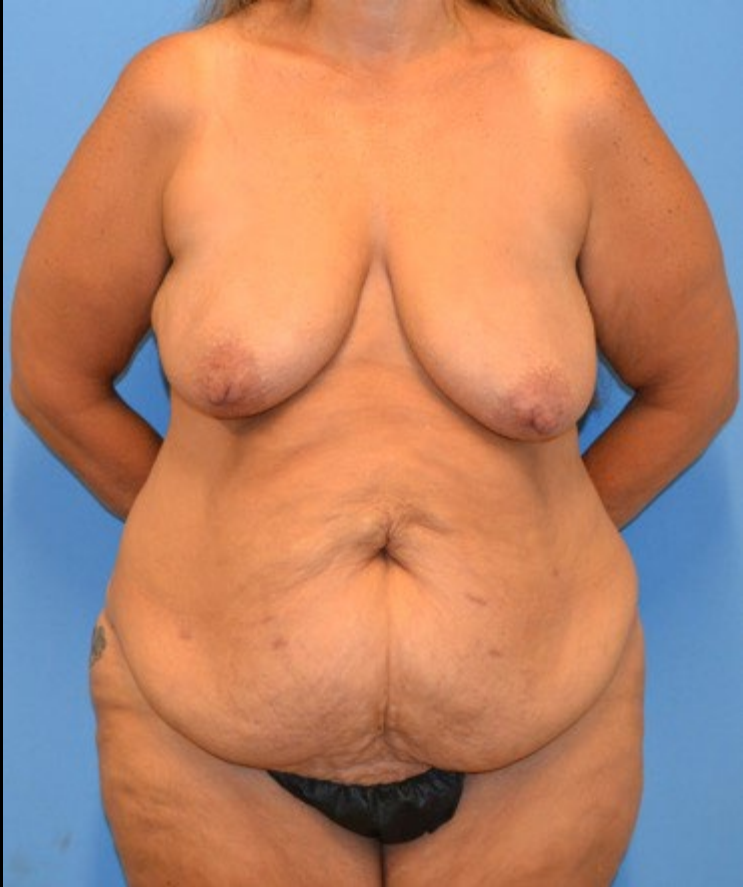
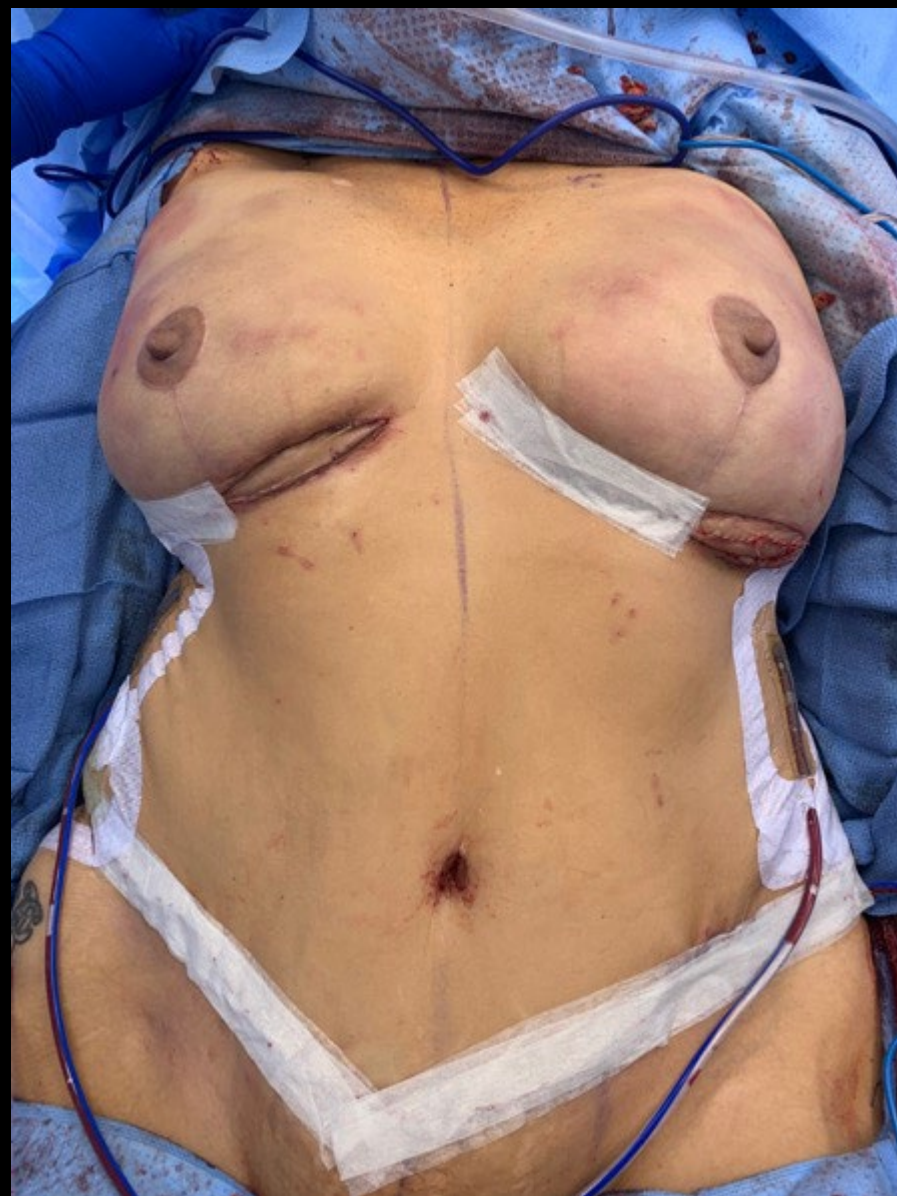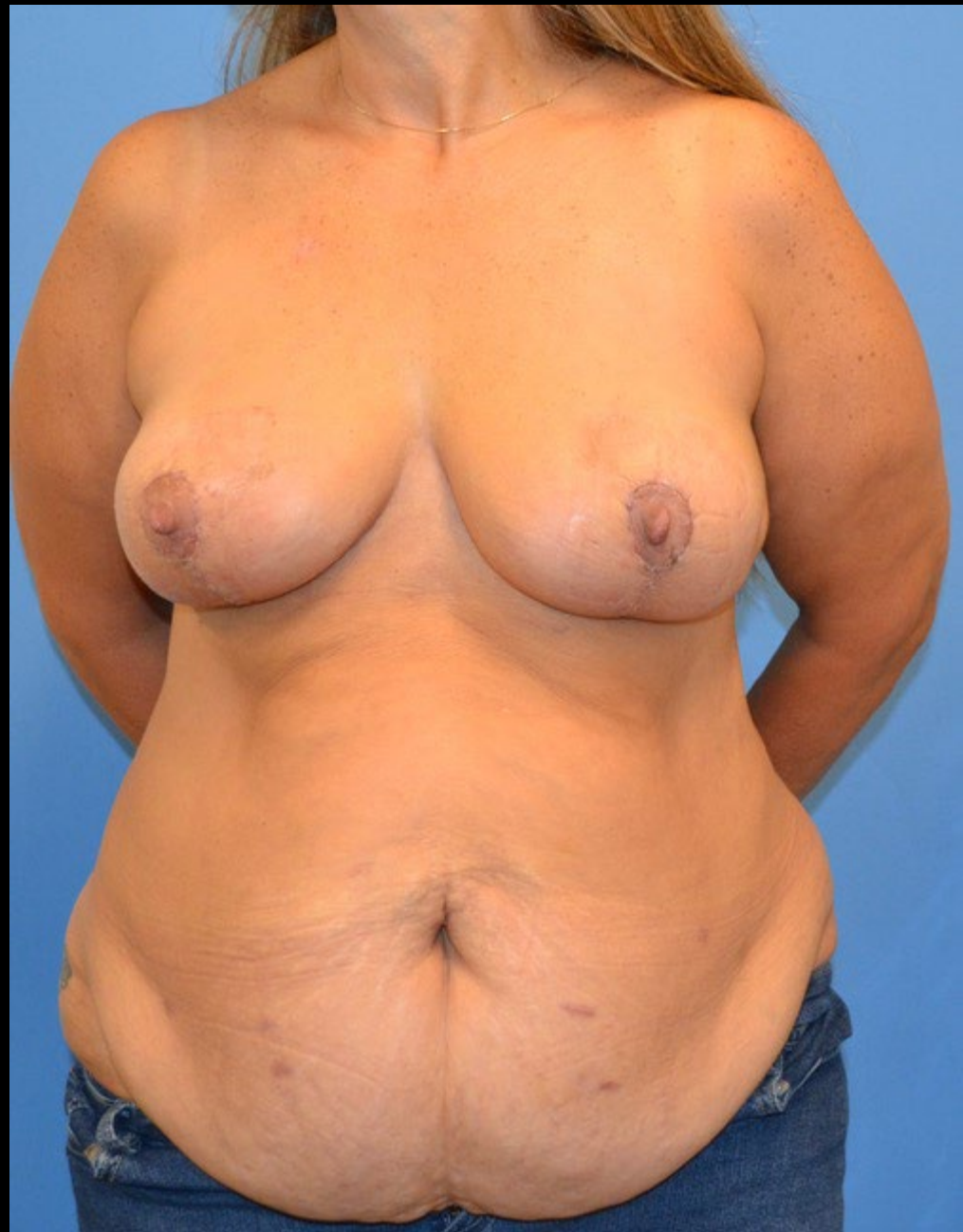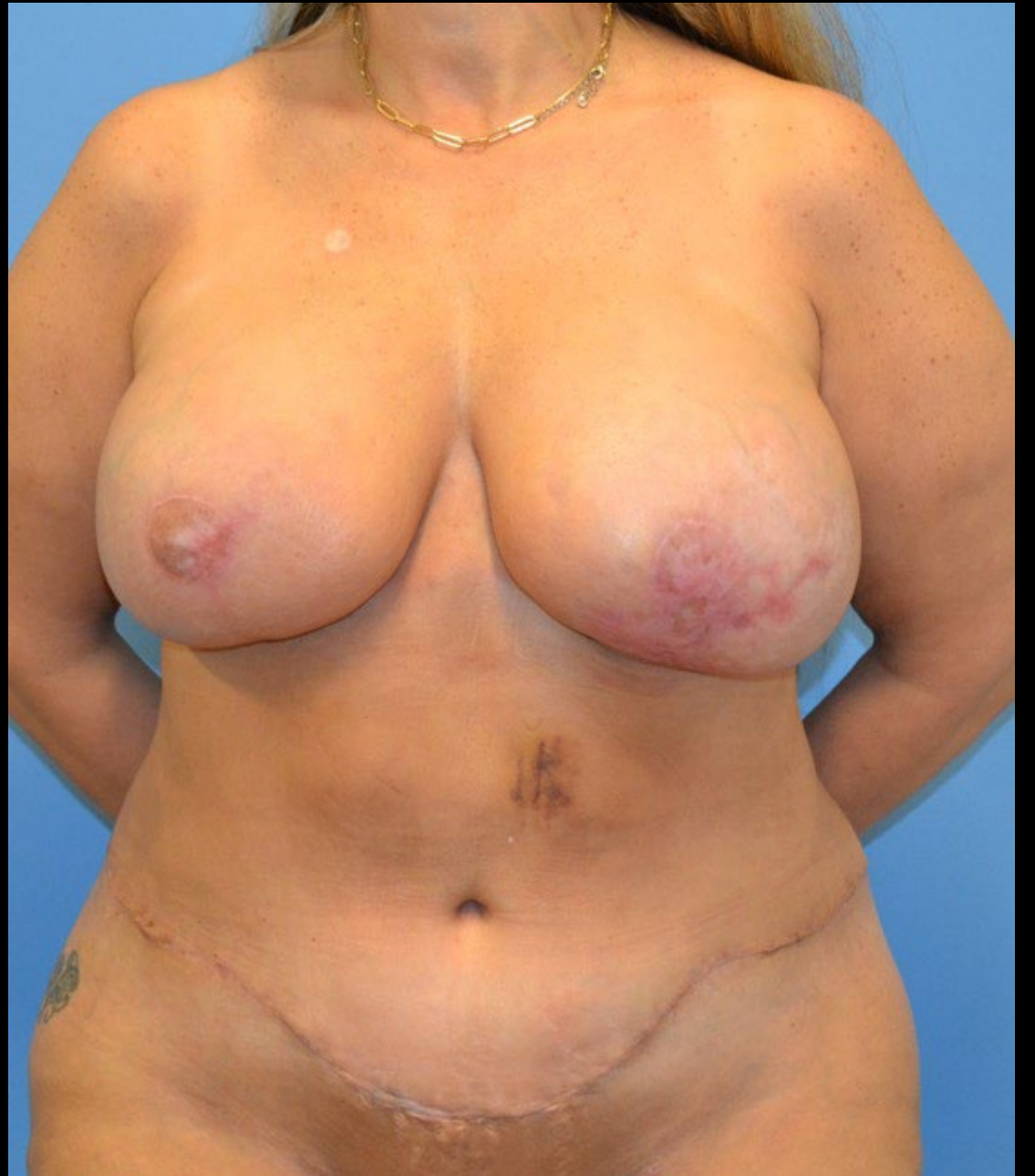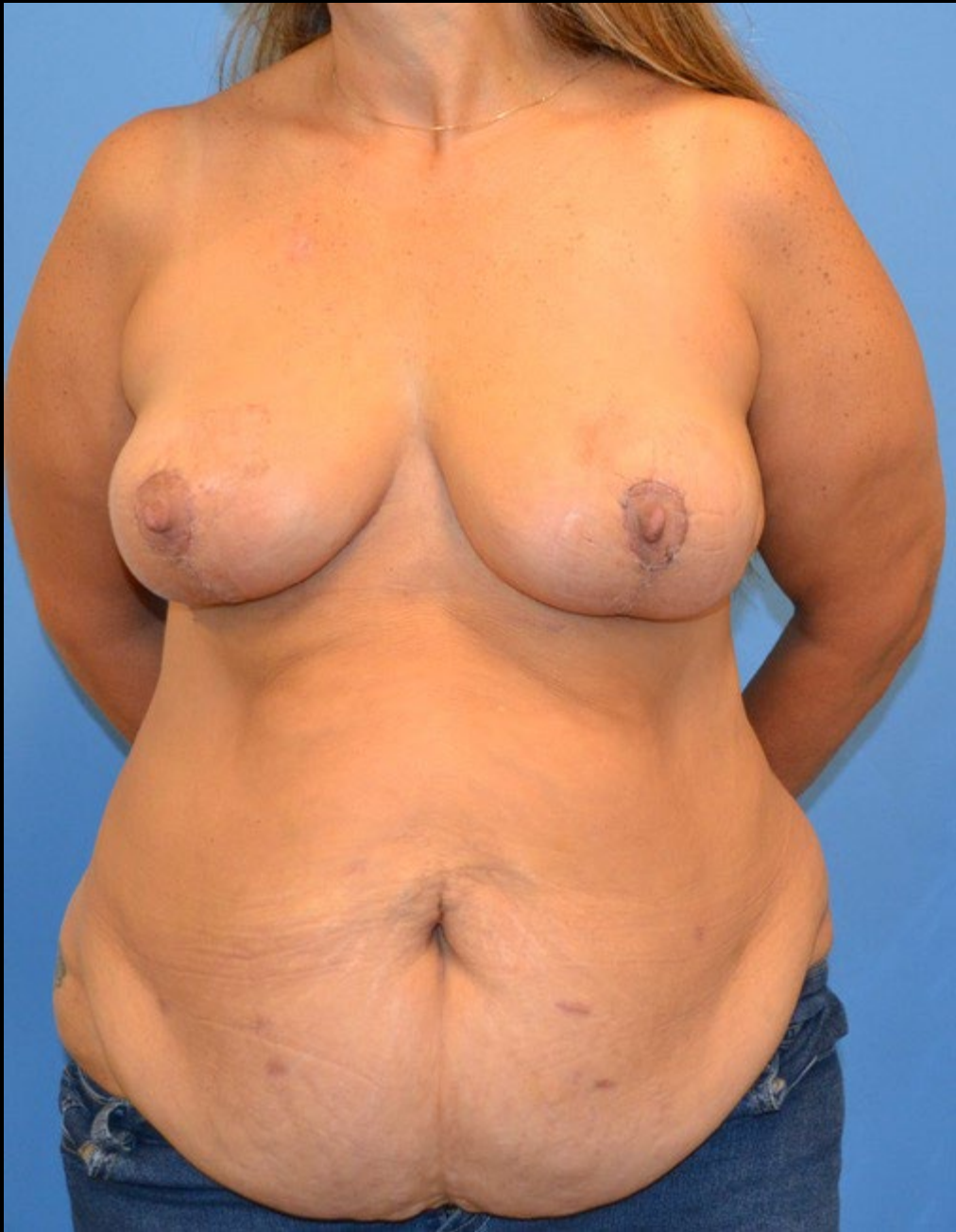# Staged Mastopexy vs. Breast Reduction

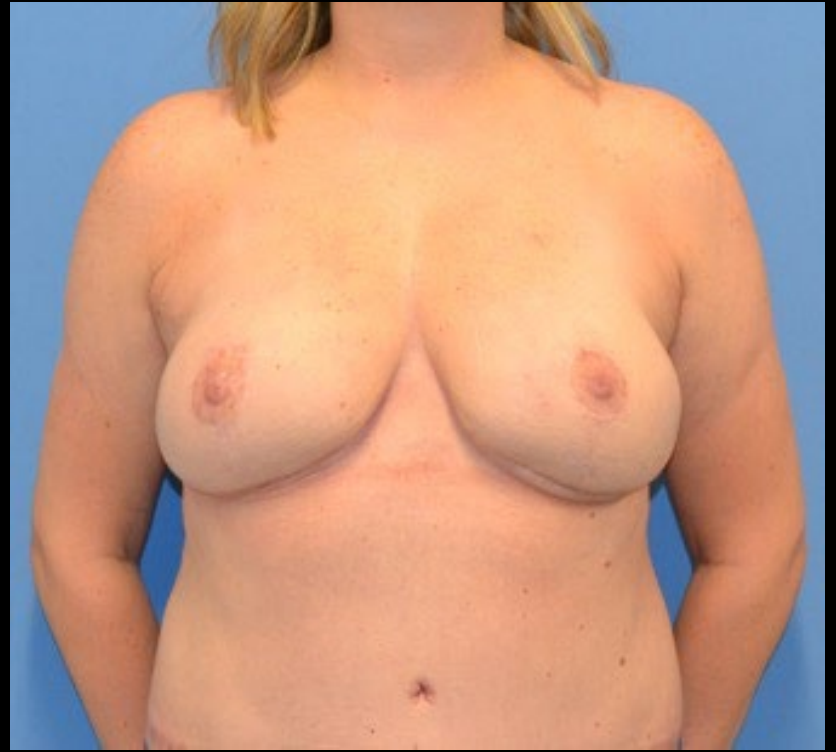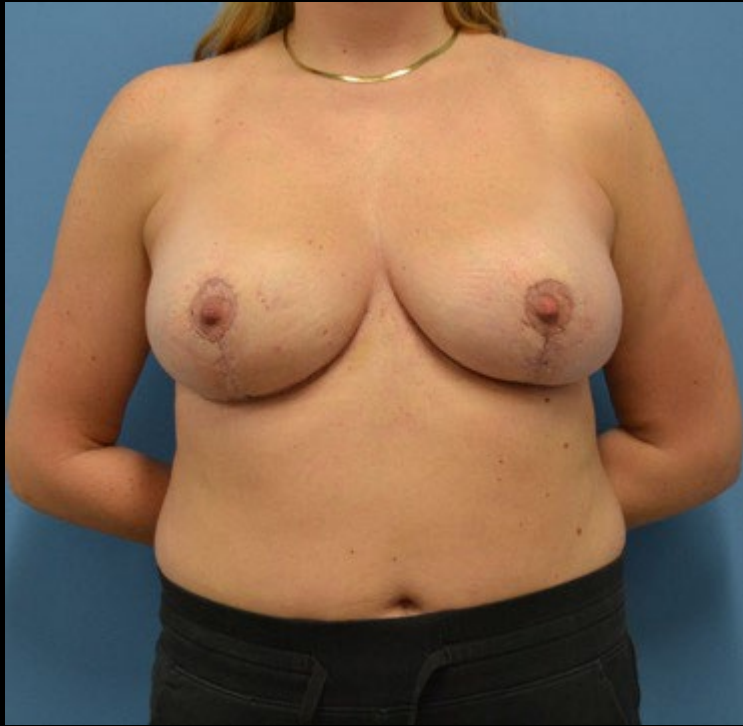

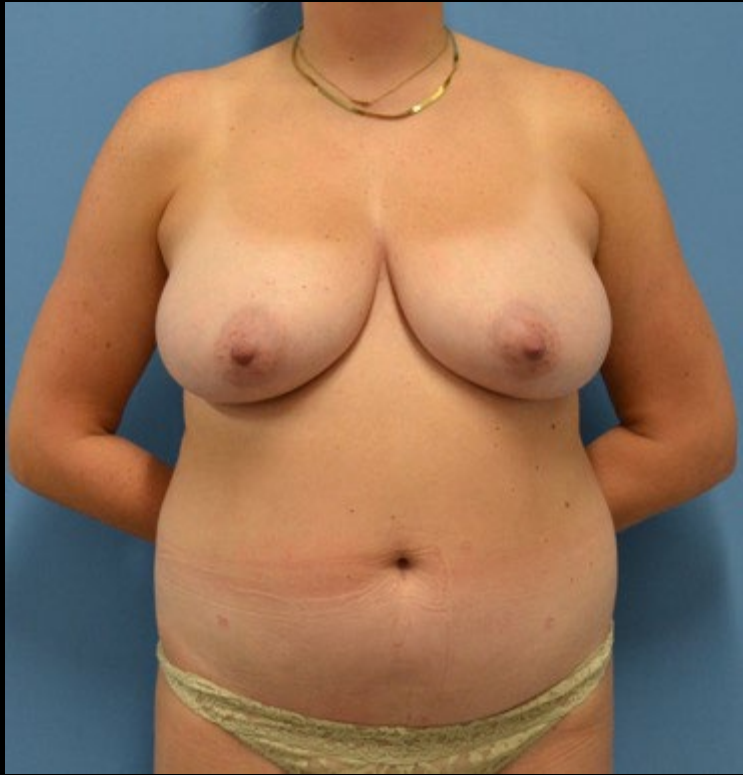


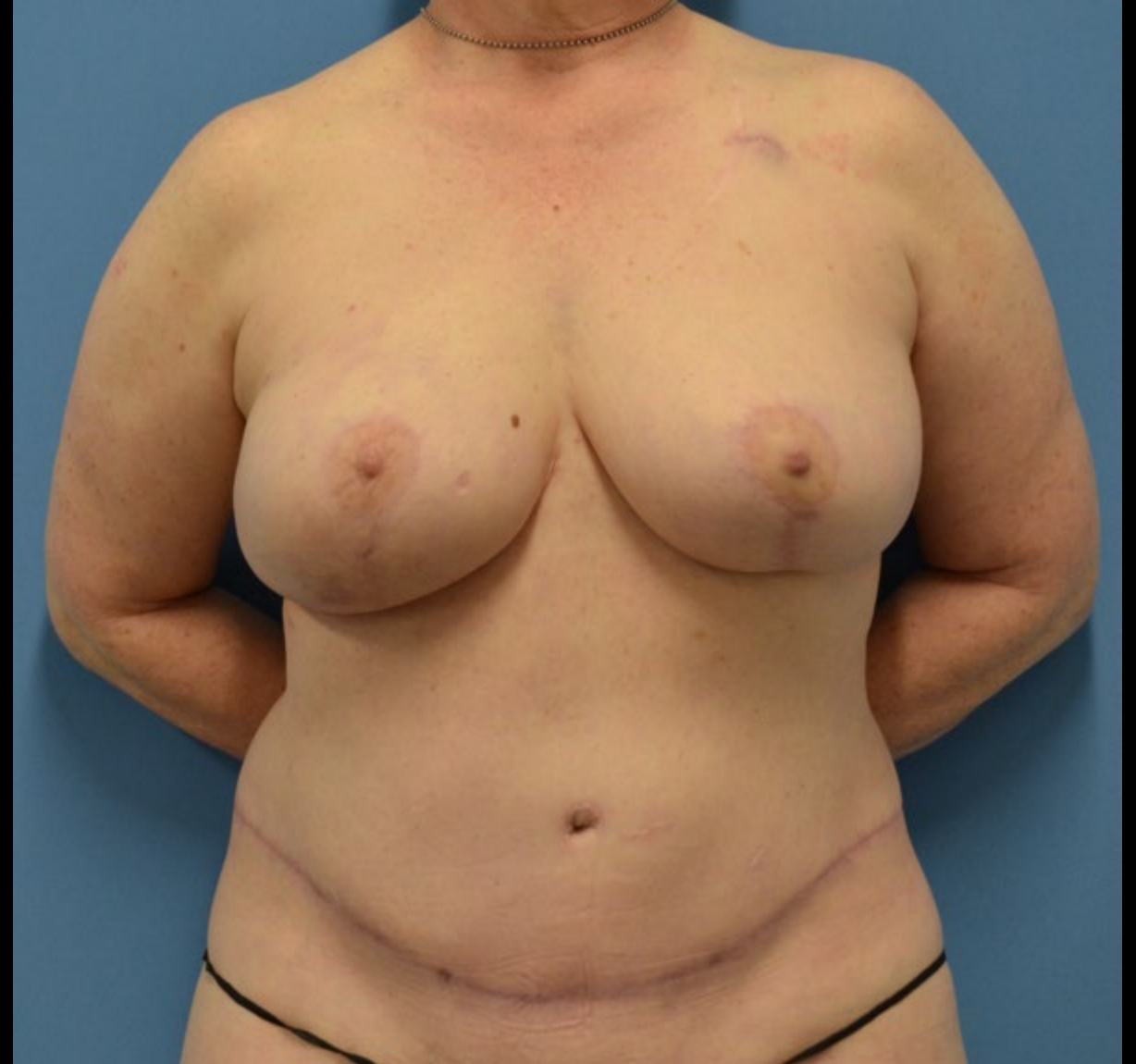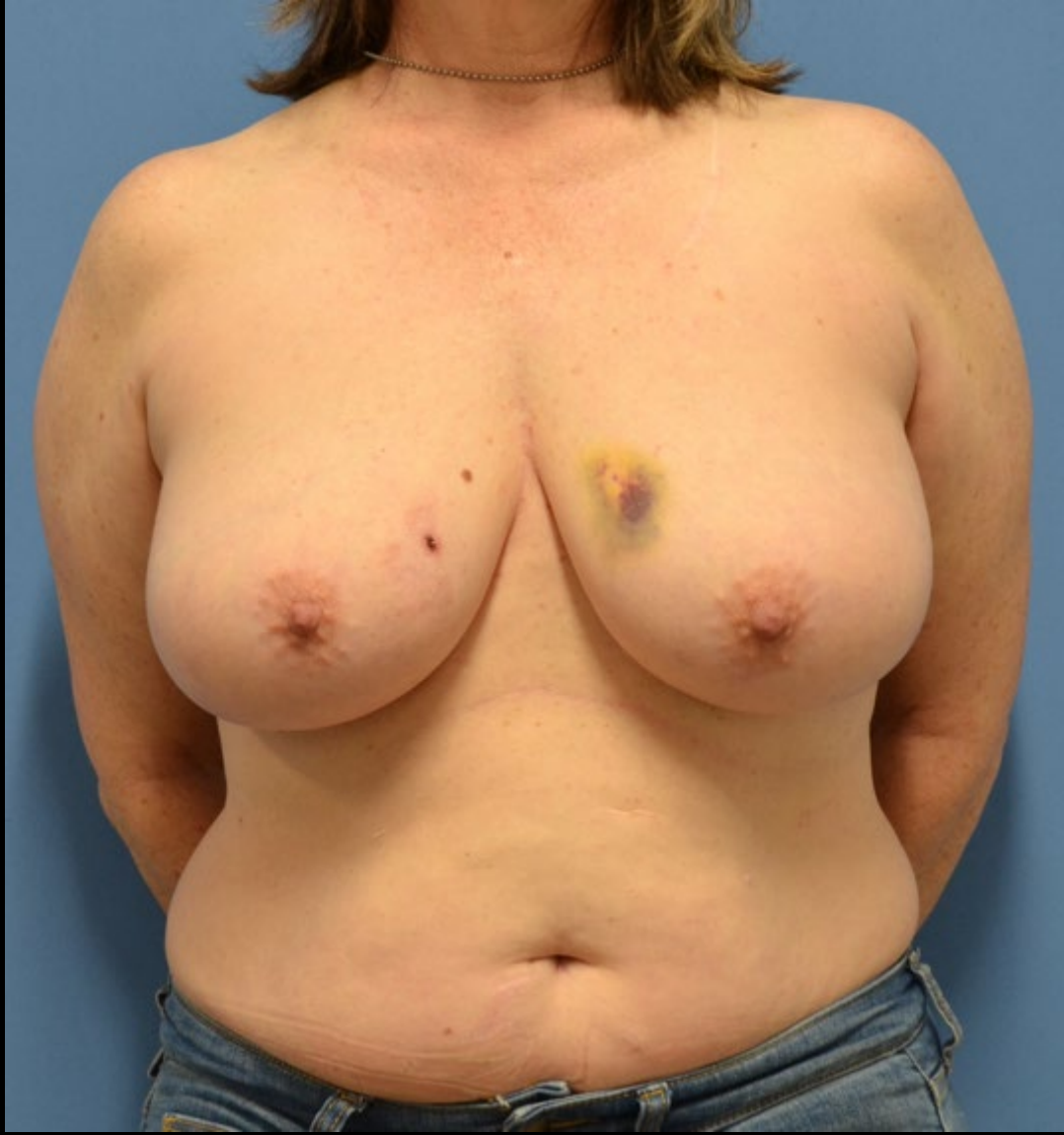- BRCA1 Positive
- Mastopexy
- Nipple sparing mastectomy and immediate DIEP reconstruction









- Standards for breast reconstruction have changed
- “Cosmetic” results are expected
- The envelope must be pushed to achieve elevated outcomes
- Partnership with Breast Surgical Oncology is critical



Thank You!

[meredith.collins@ochsner.org](mailto:meredith.collins@ochsner.org)